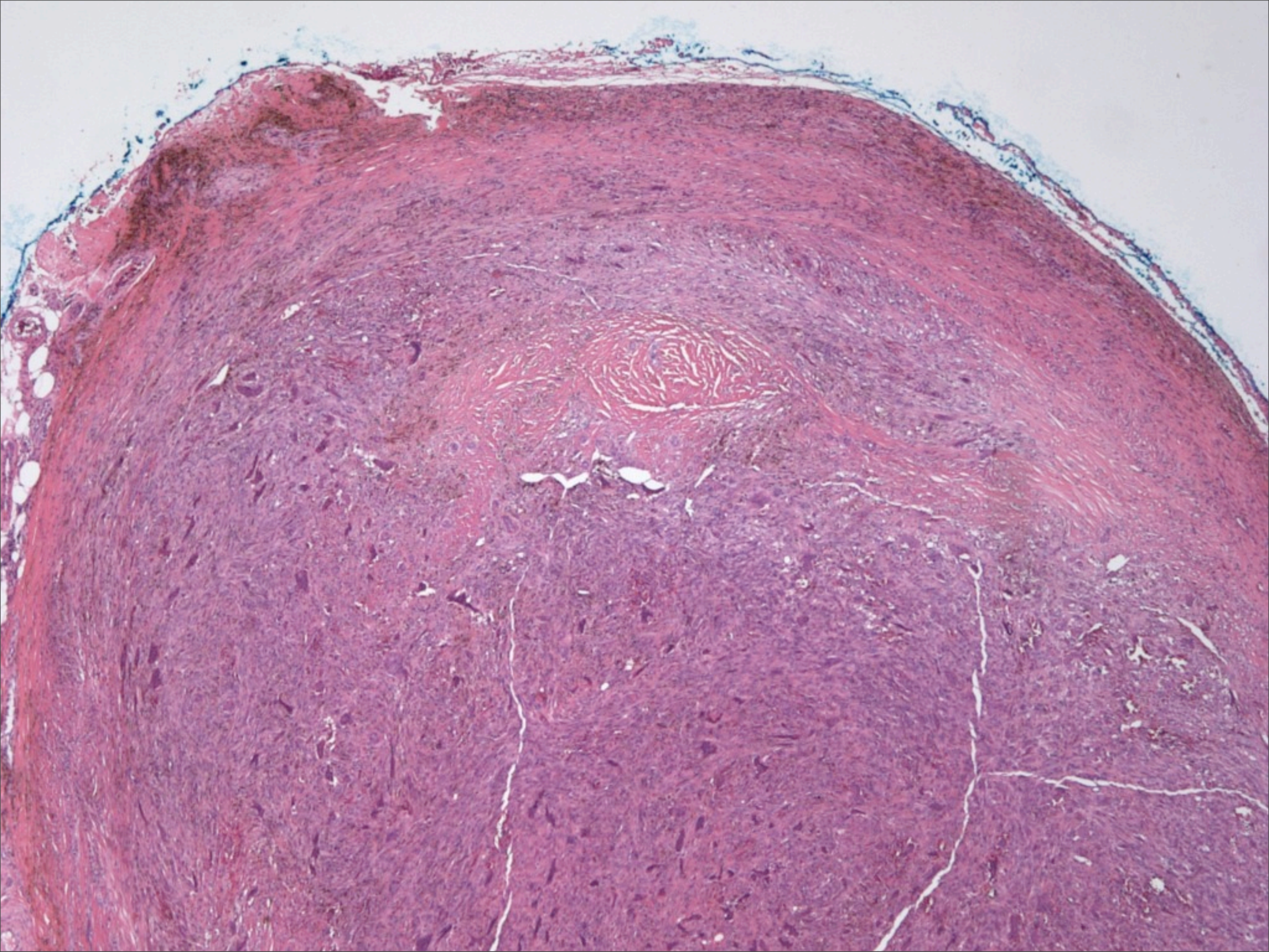
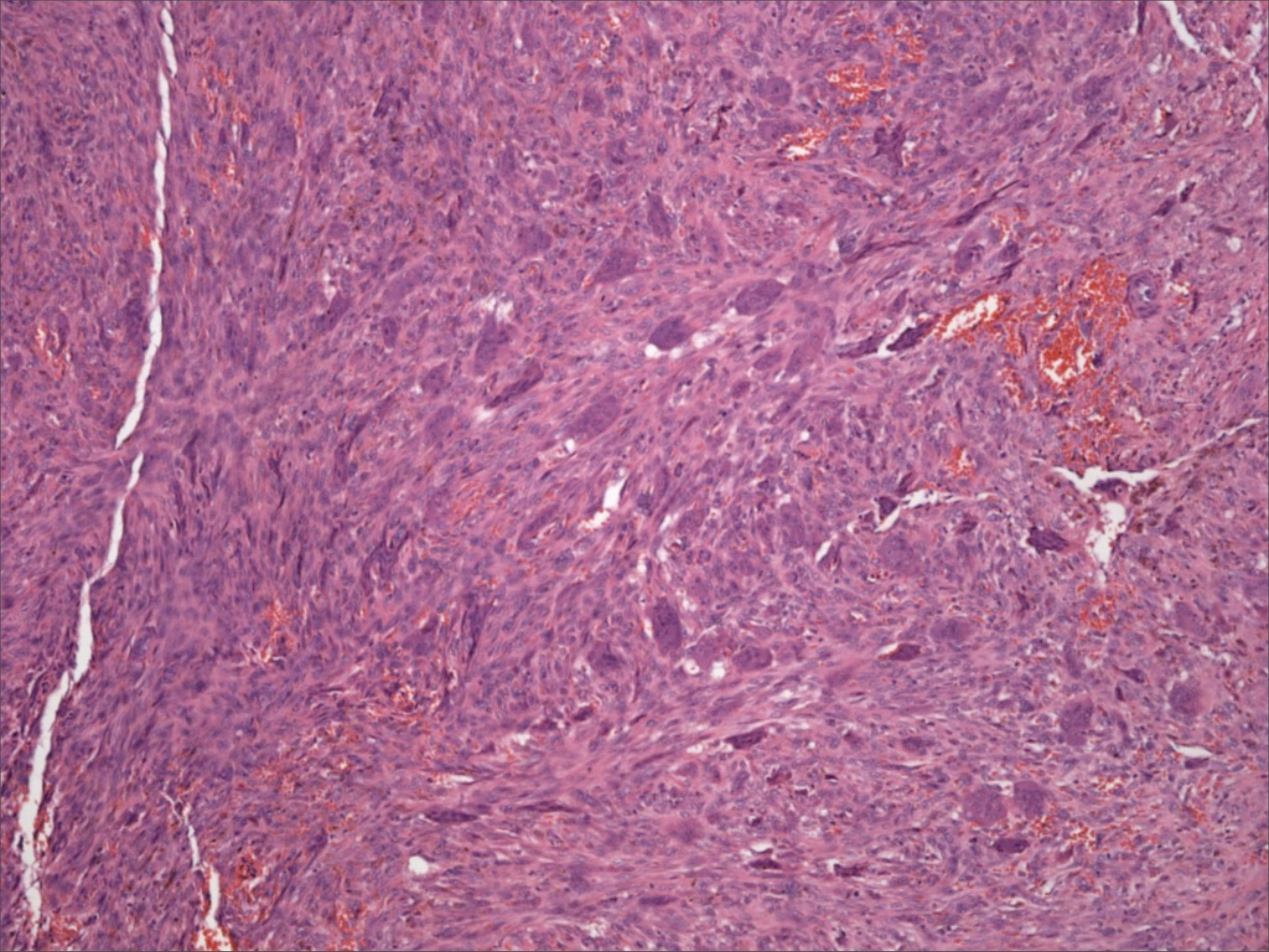


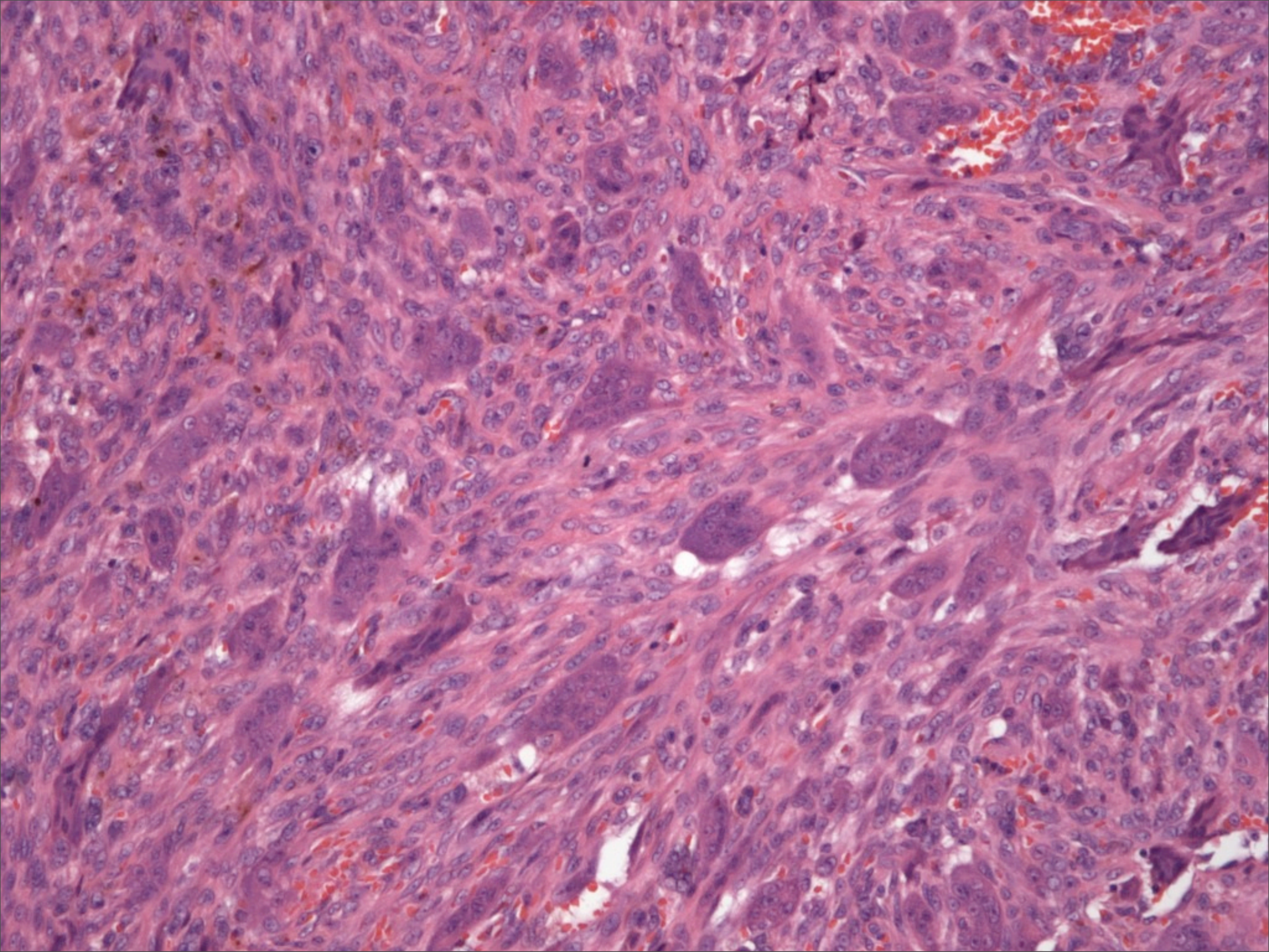
Dermatopathology

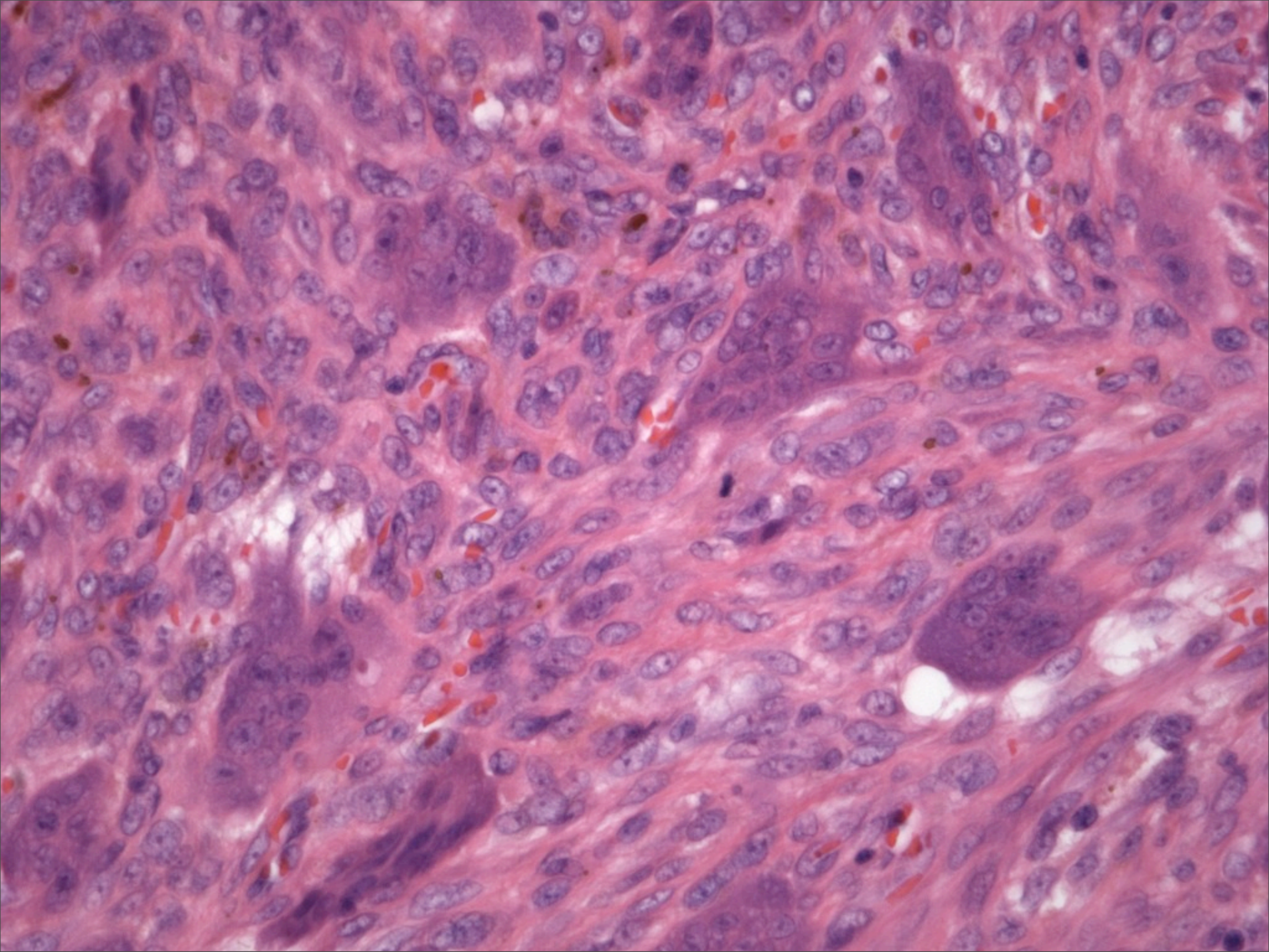
Slide Review Part 157

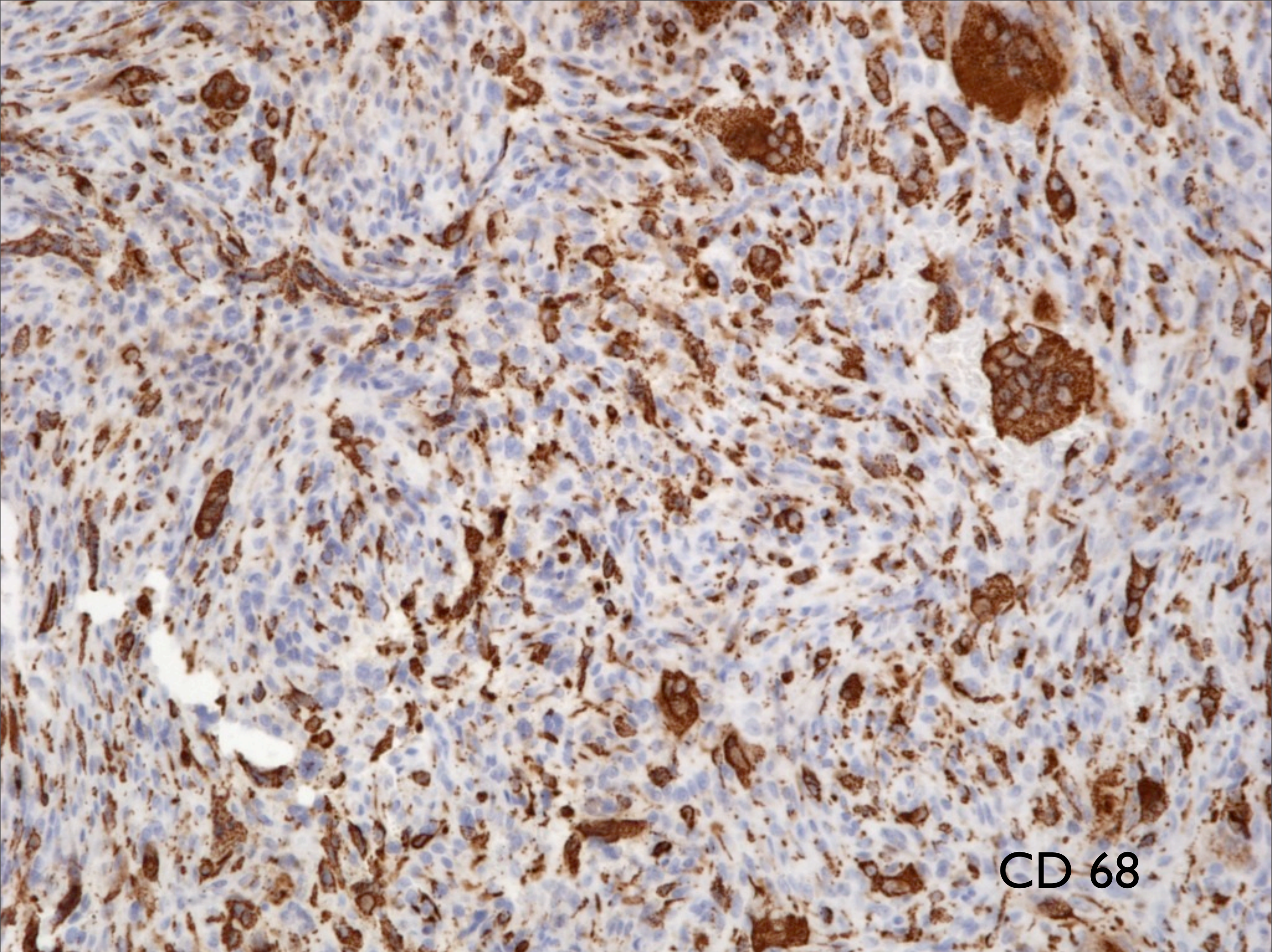
Paul K. Shitabata, M.D.
Dermatopathology Institute
Torrance, CA



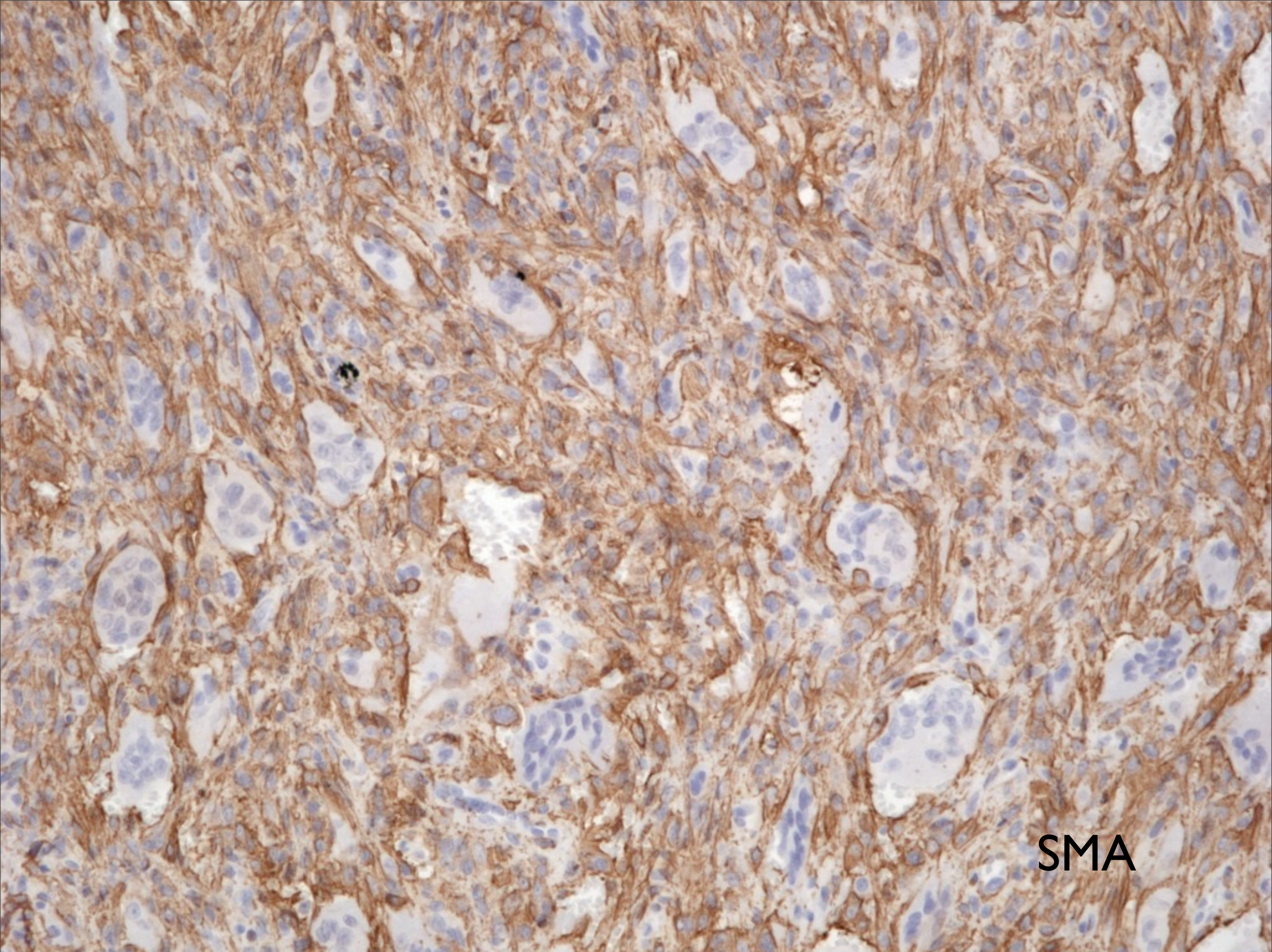








CD 68

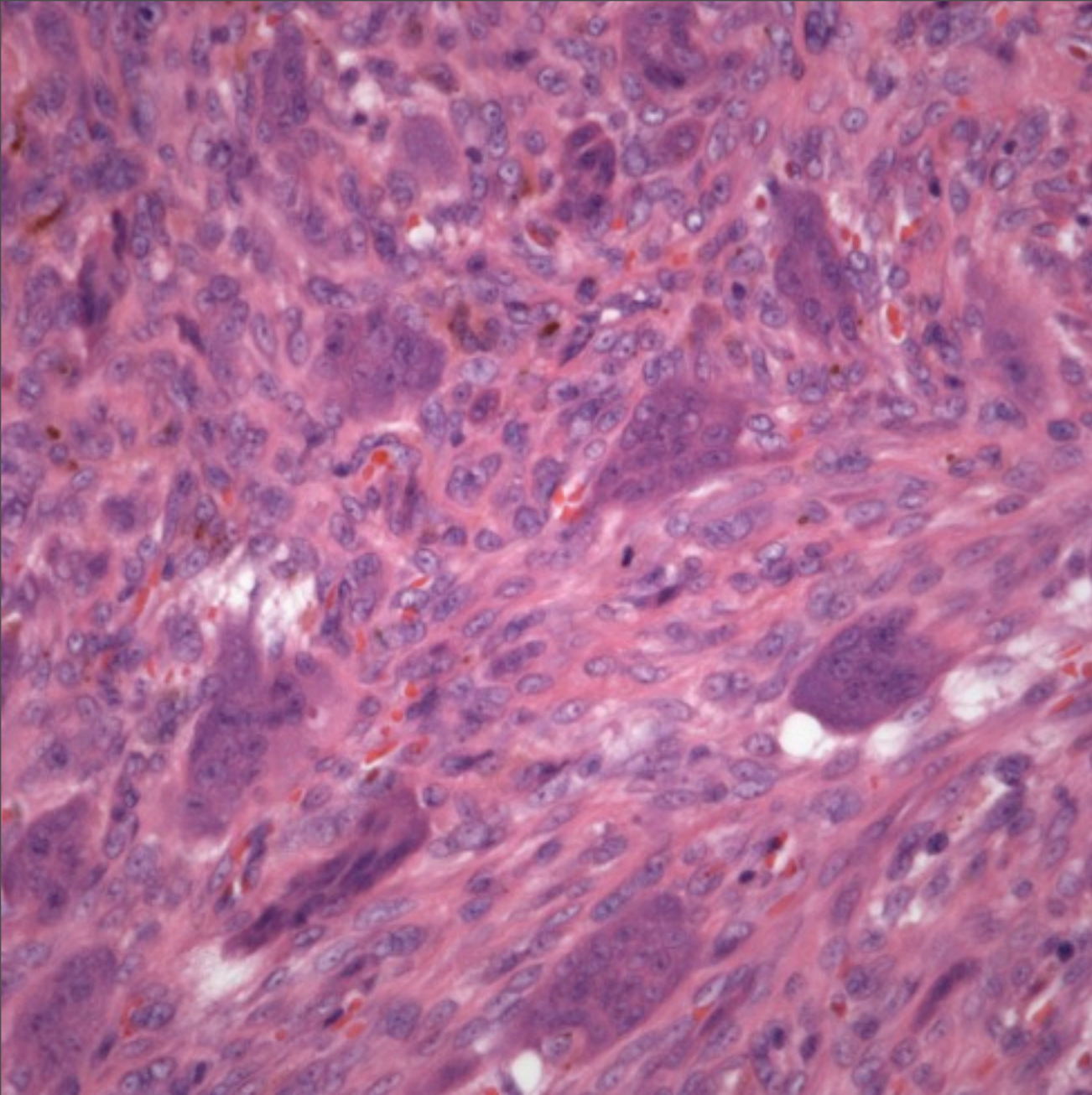


SMA

Soft Tissue Giant Cell Tumor of Low Malignant Potential

Notes

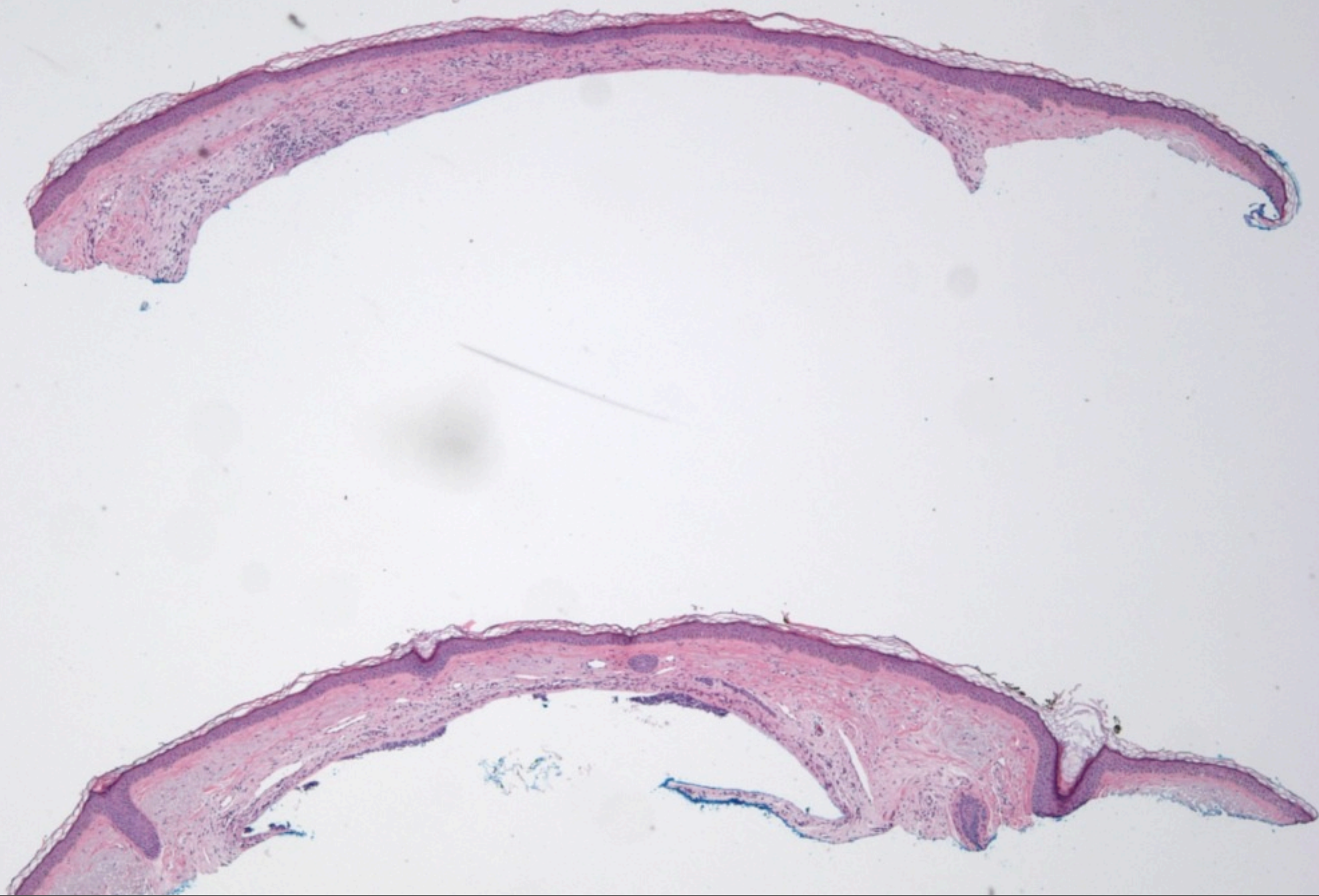
- This is a rare soft tissue neoplasm that histologically resembles giant cell tumor of the tendon sheath
- Mitotic rate is brisk but cellular atypia is minimal
- Differential diagnosis includes a malignant fibrous histiocytoma with giant cells. In this latter tumor, there is marked cytologic pleomorphism

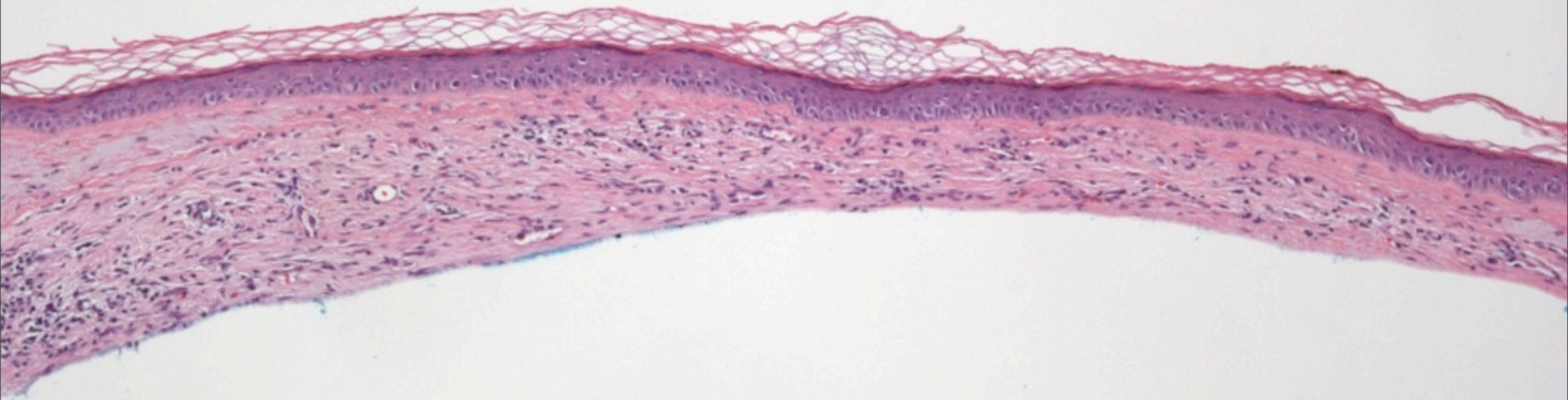


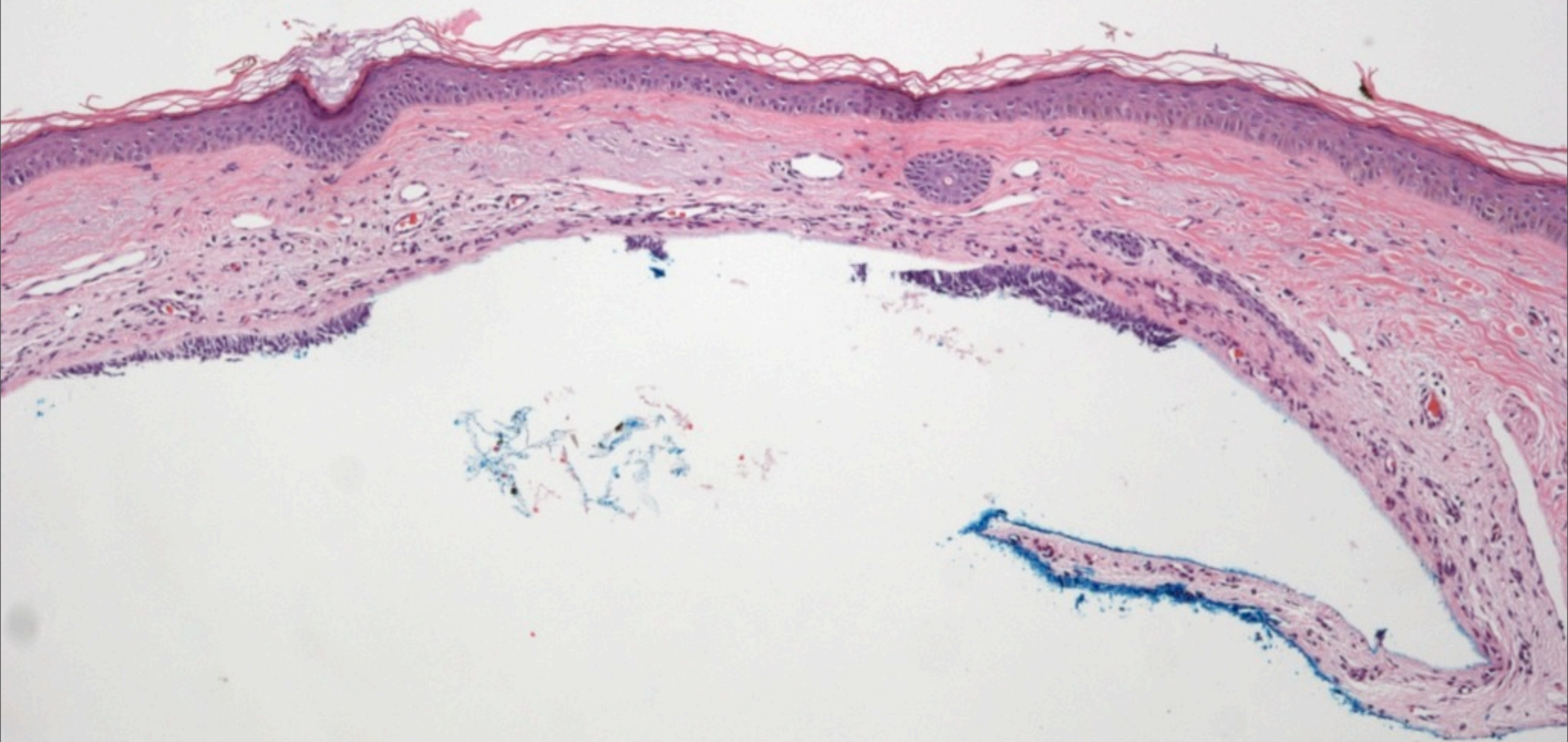
Cells positive for CD68 and
Smooth Muscle Actin

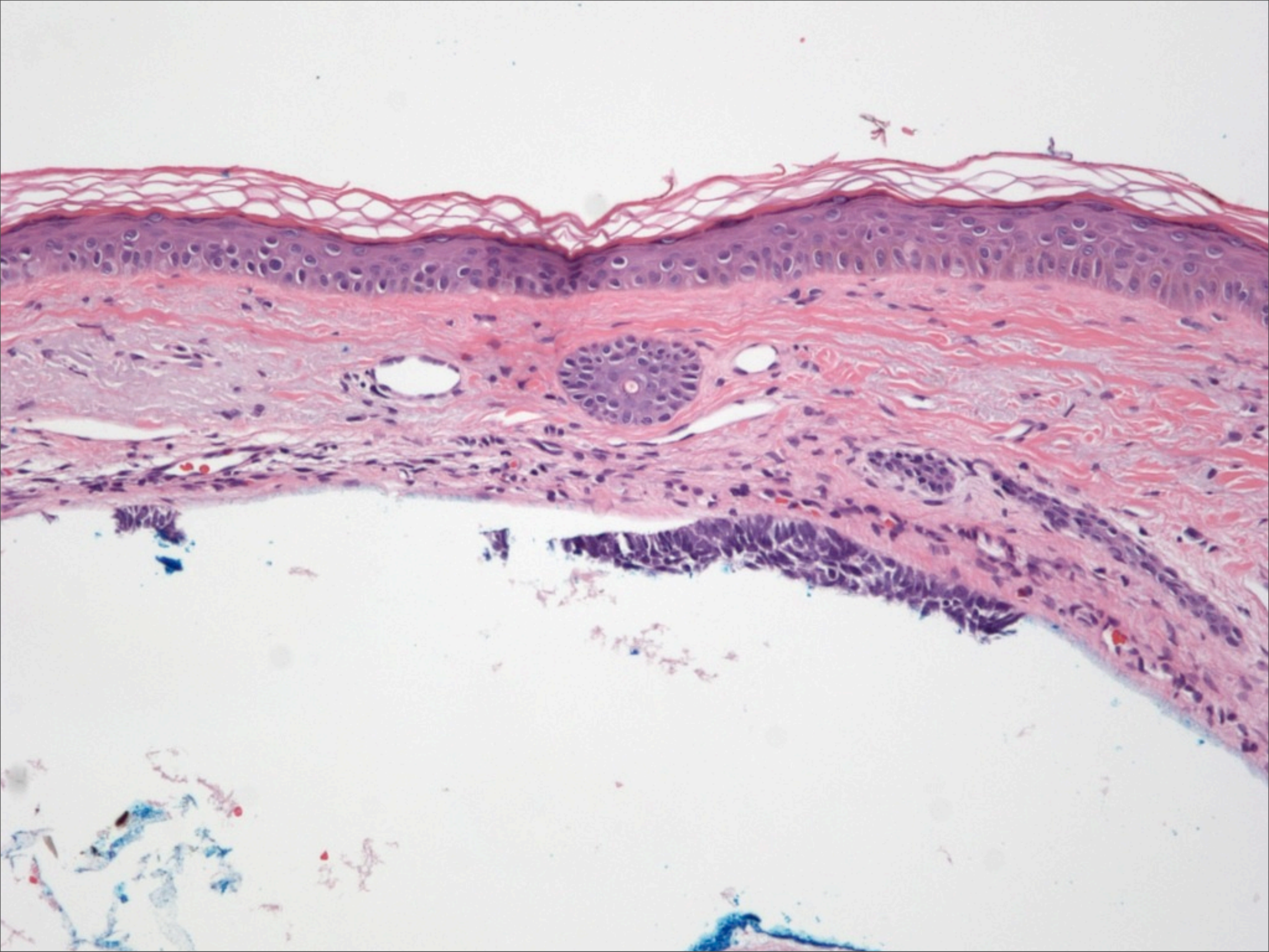
Cellular spindle cell tumor with giant cells

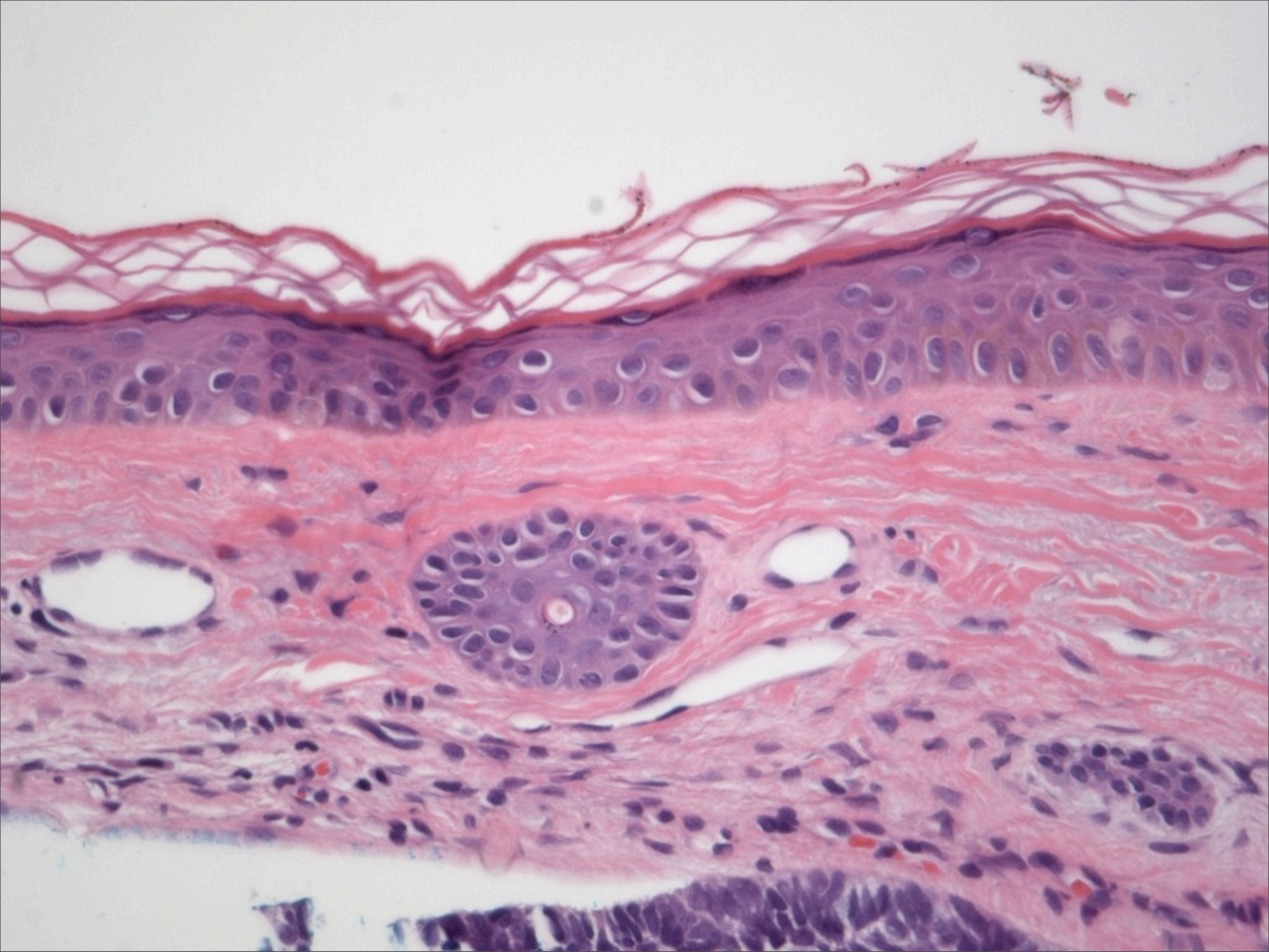
Mitotic activity is brisk but no atypical MF







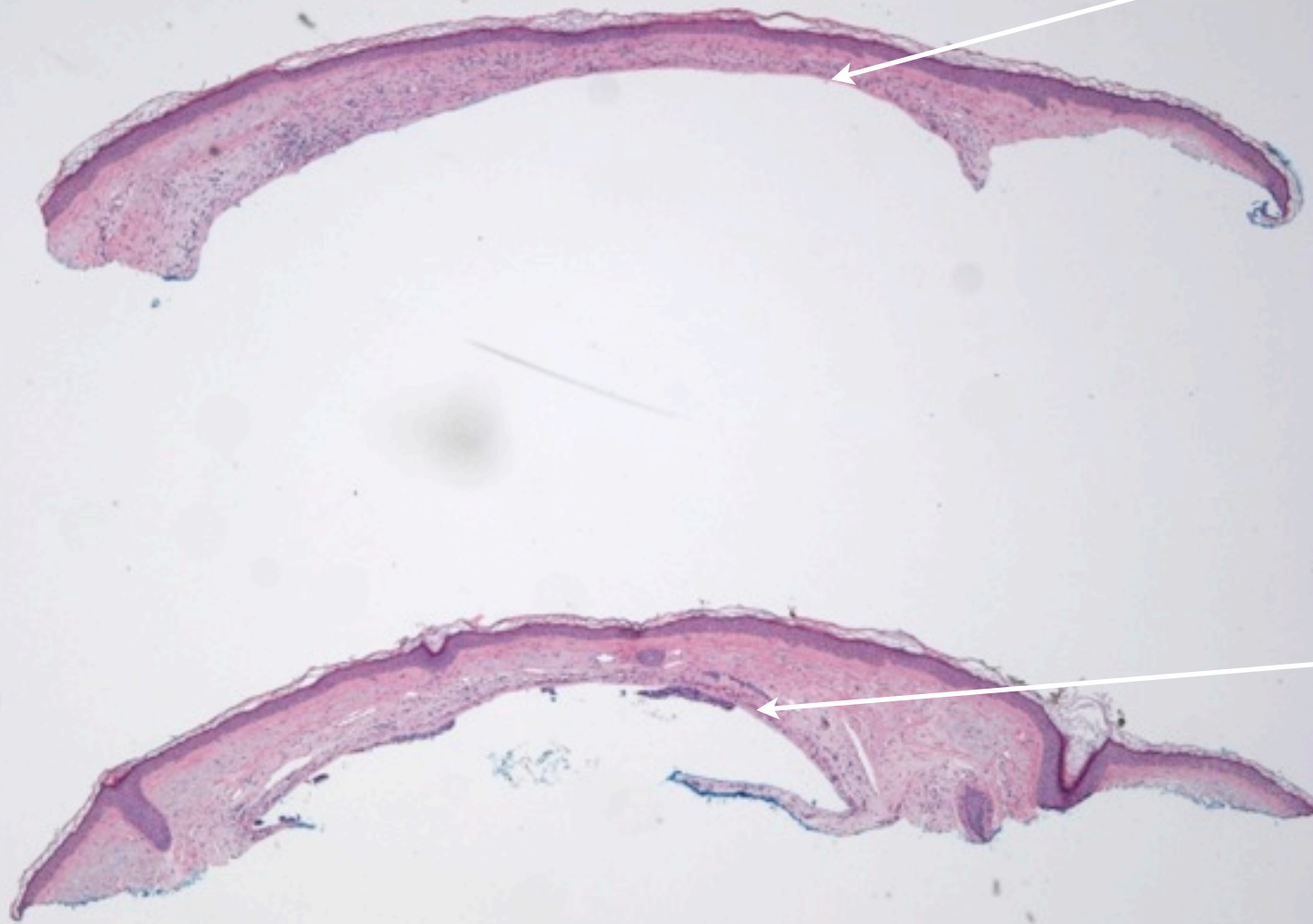


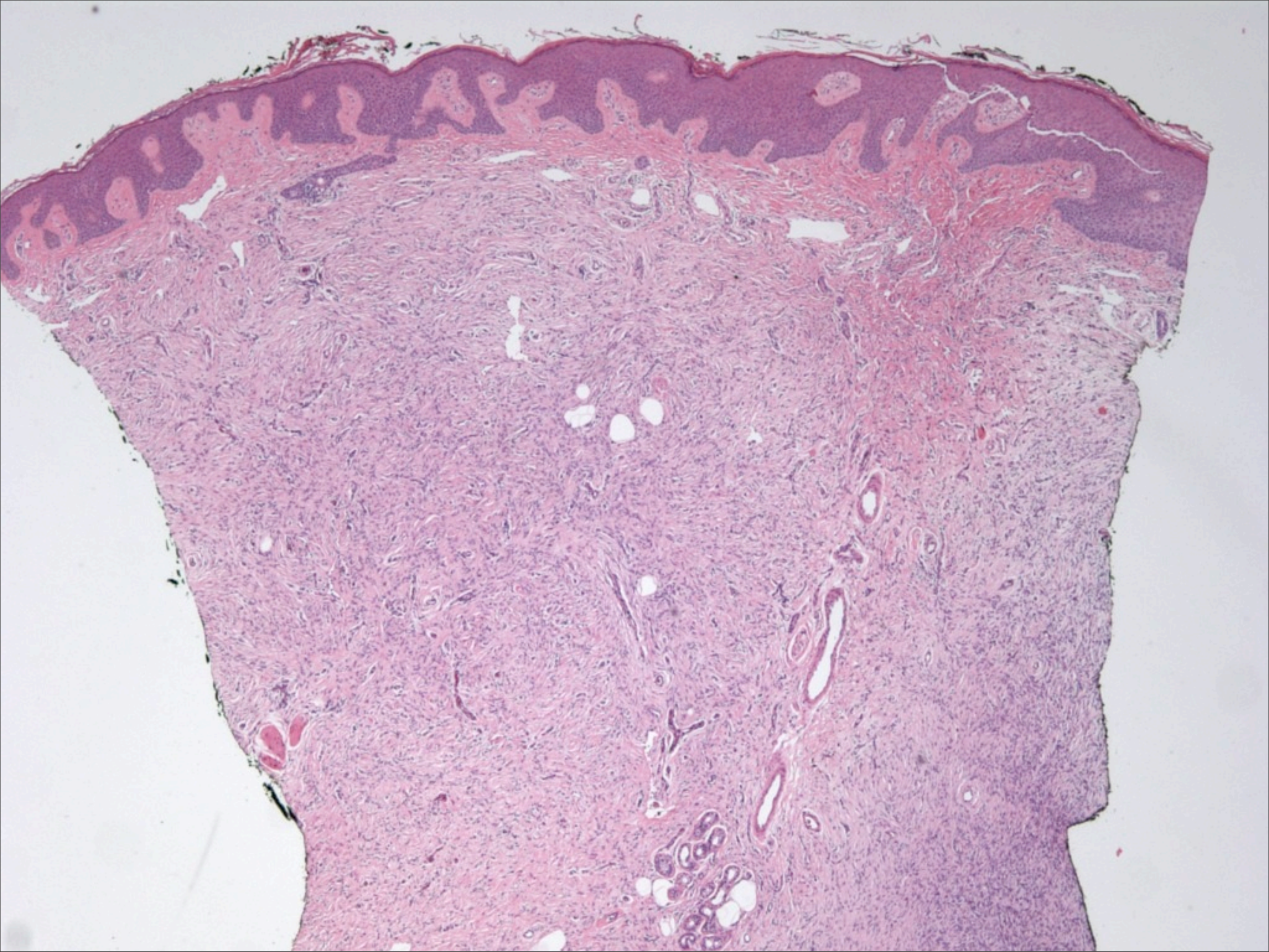


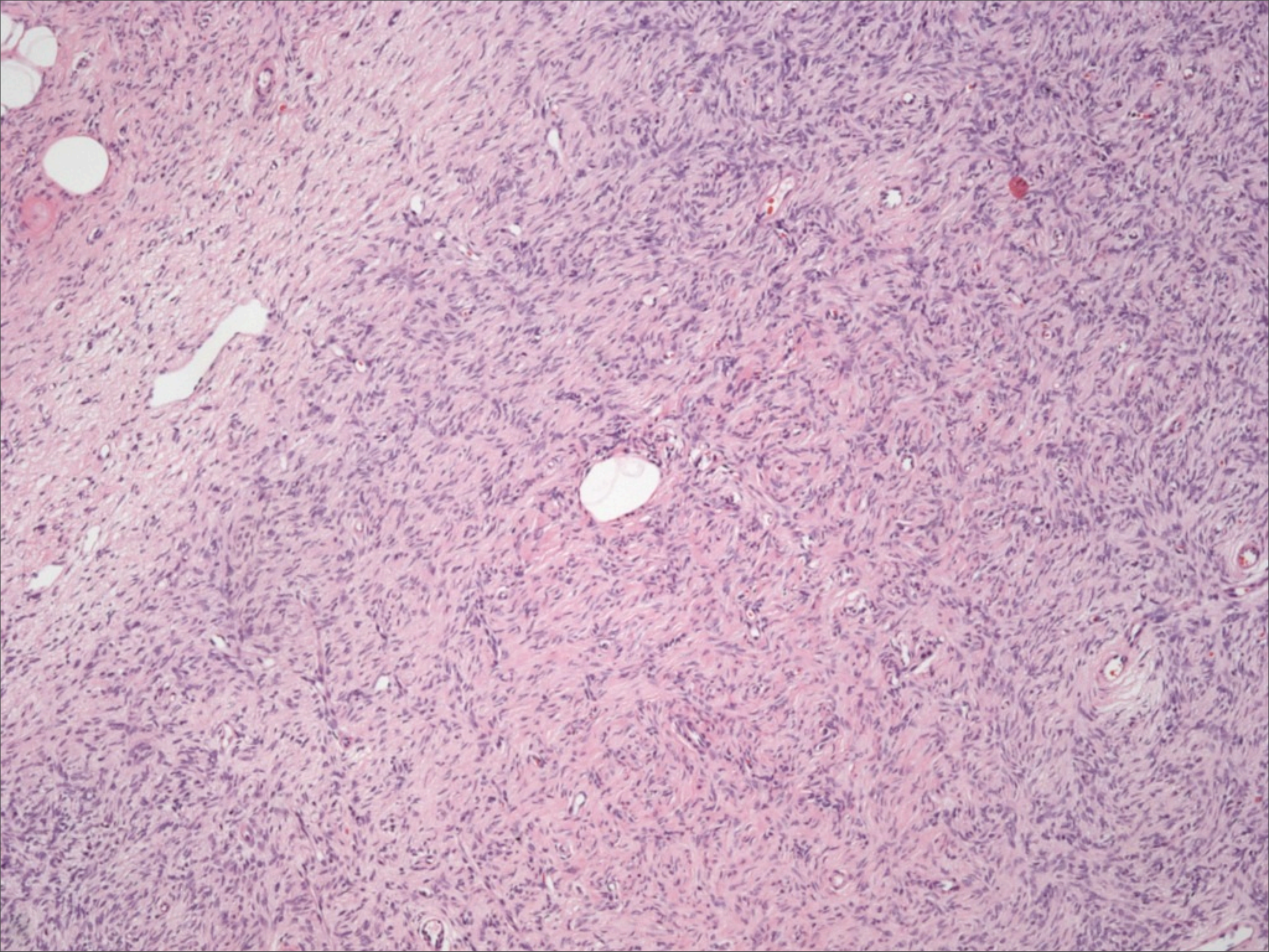
Nodular and Cystic Basal Cell Carcinoma

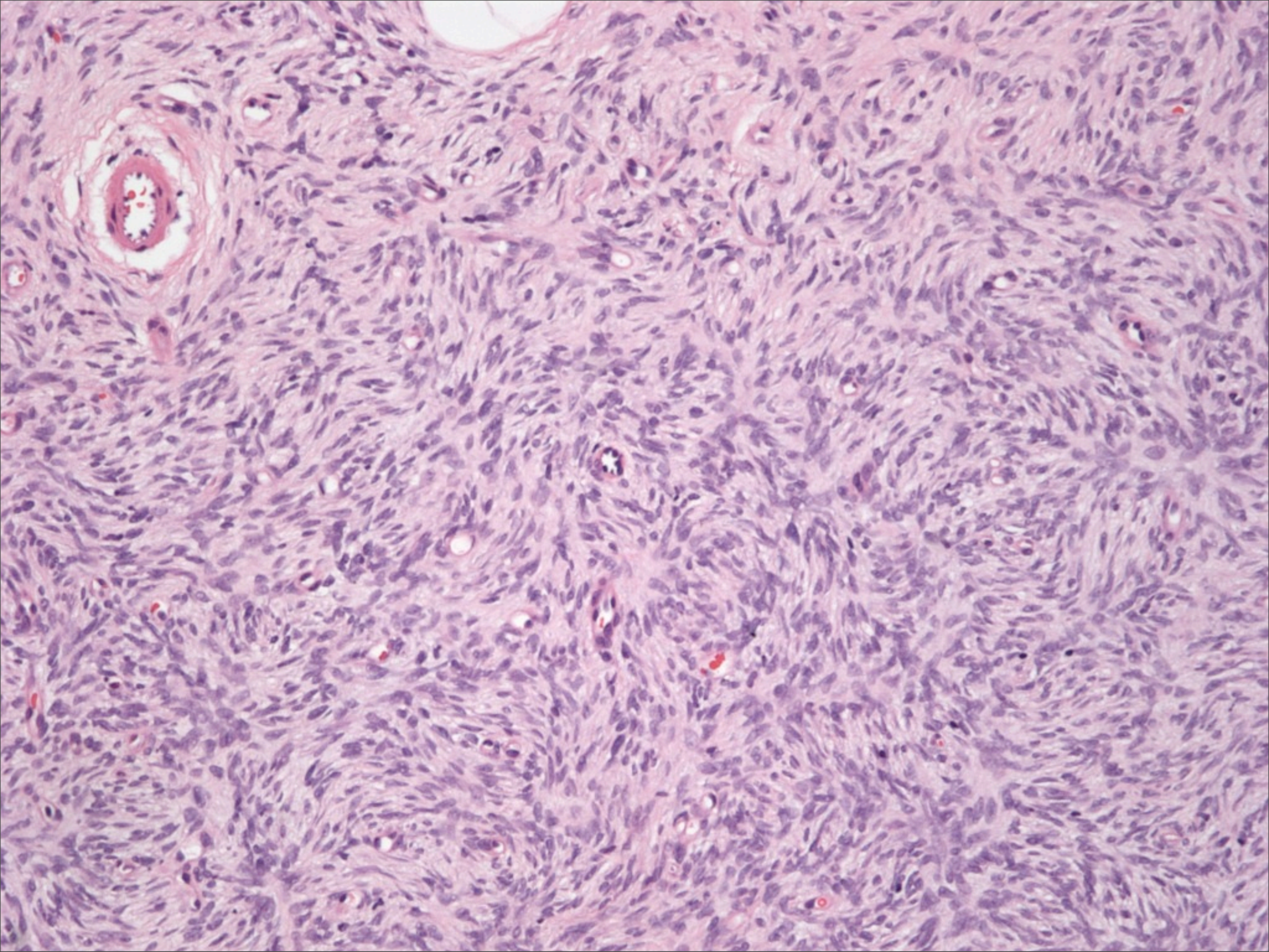
This variant of BCC
may present with an
empty cystic space

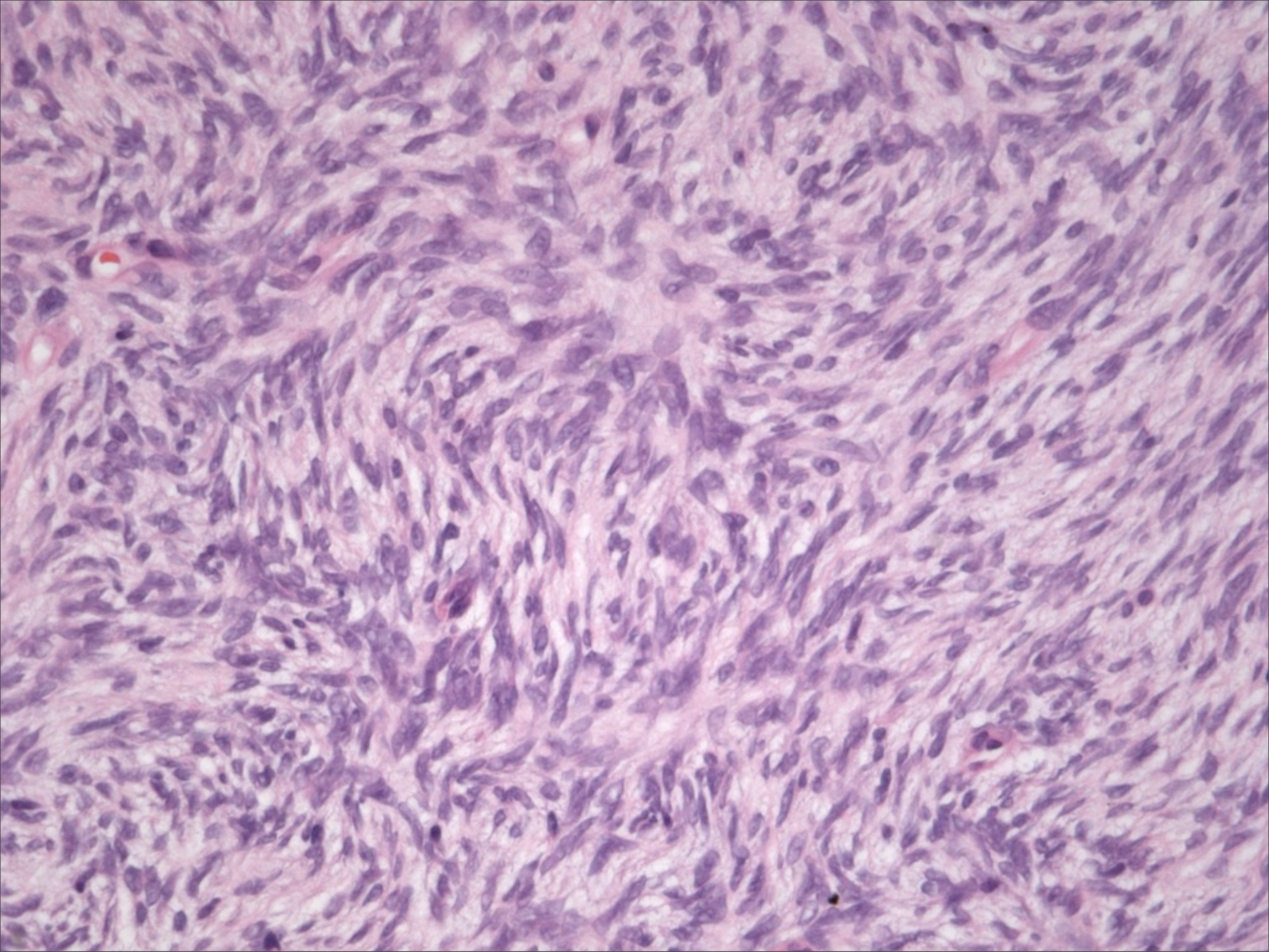
Important to cut deeper
to see the basal cells
clinging to the cavity

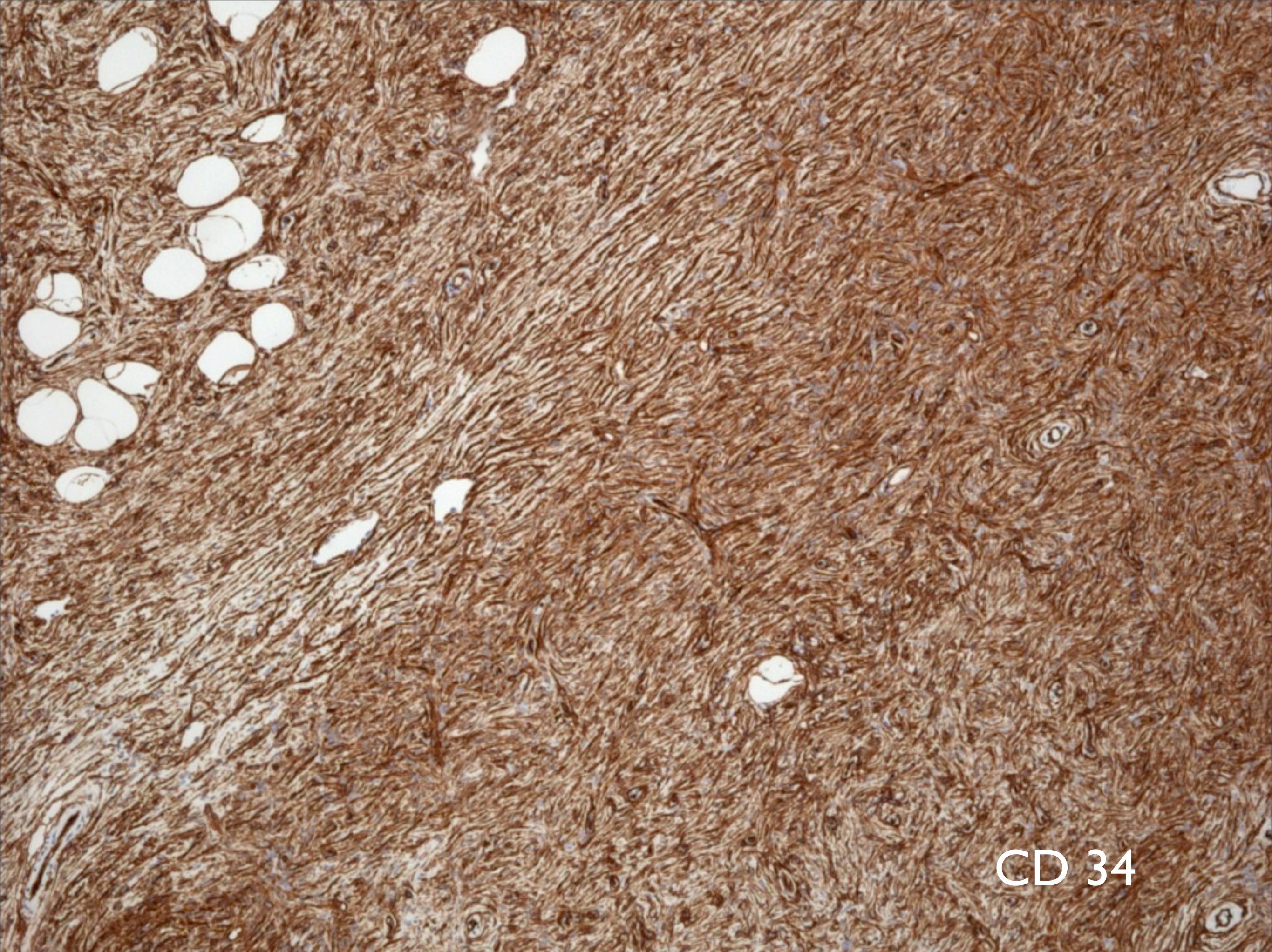






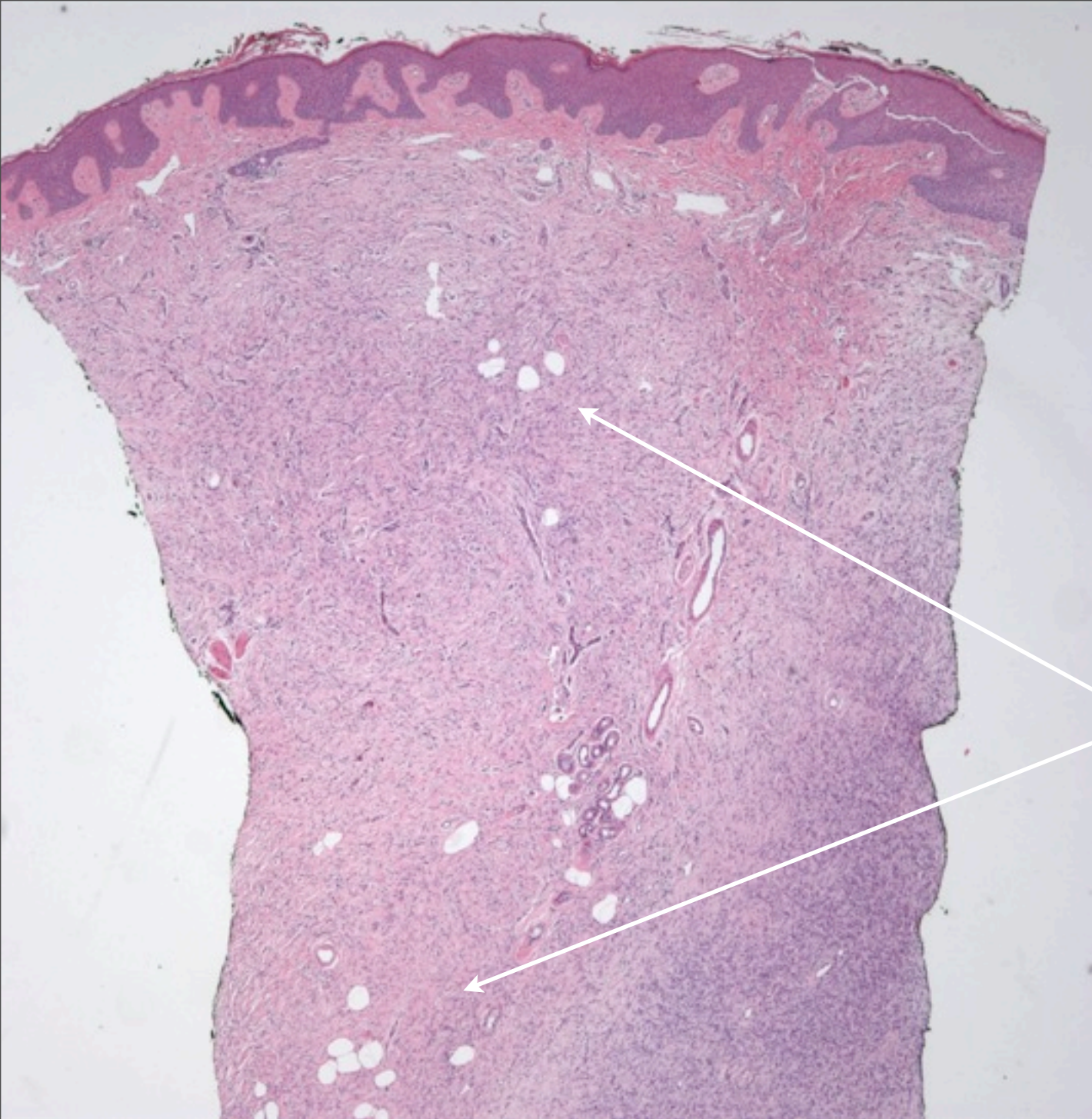






CD 34

Dermatofibrosarcoma Protuberans

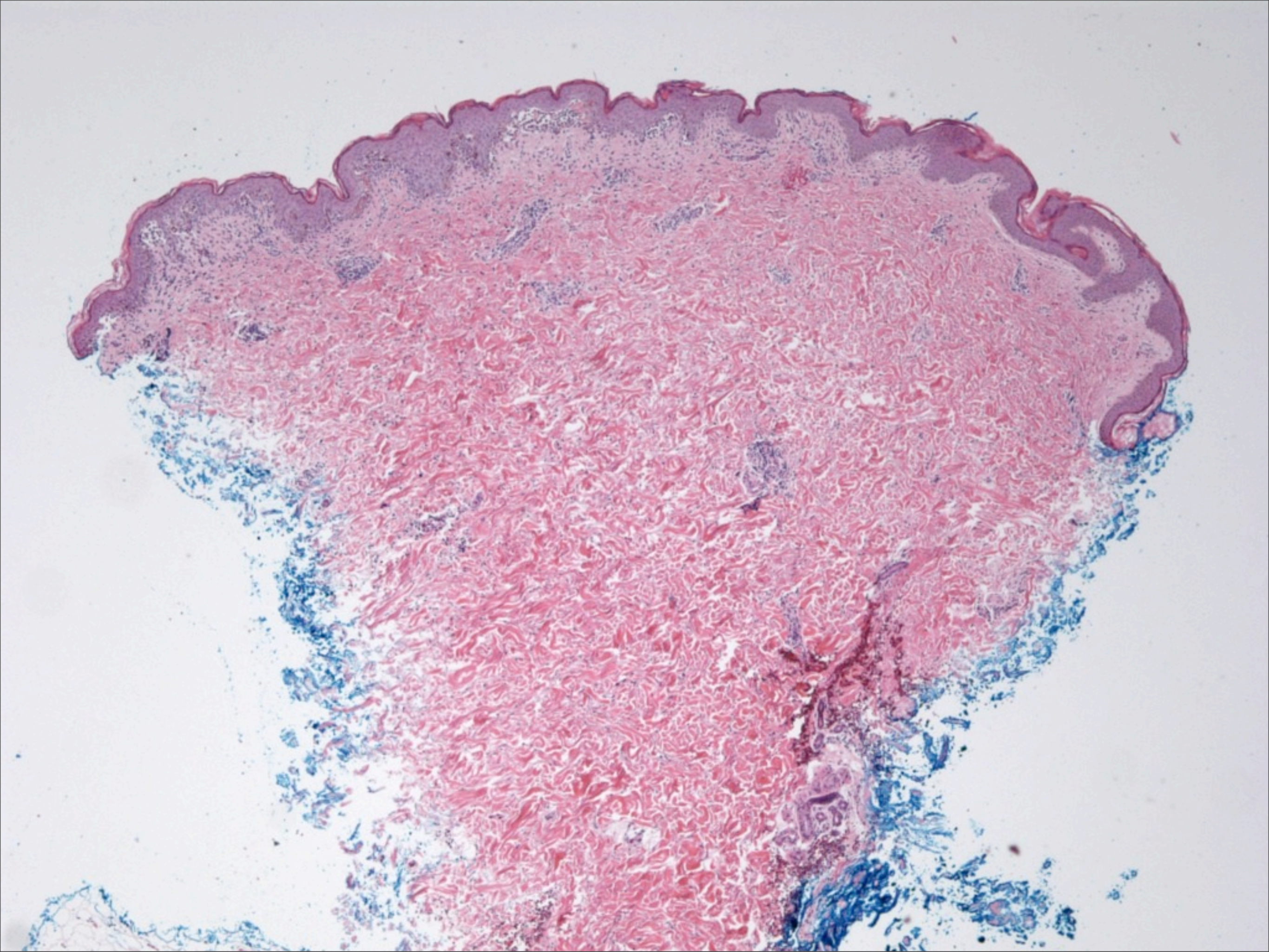


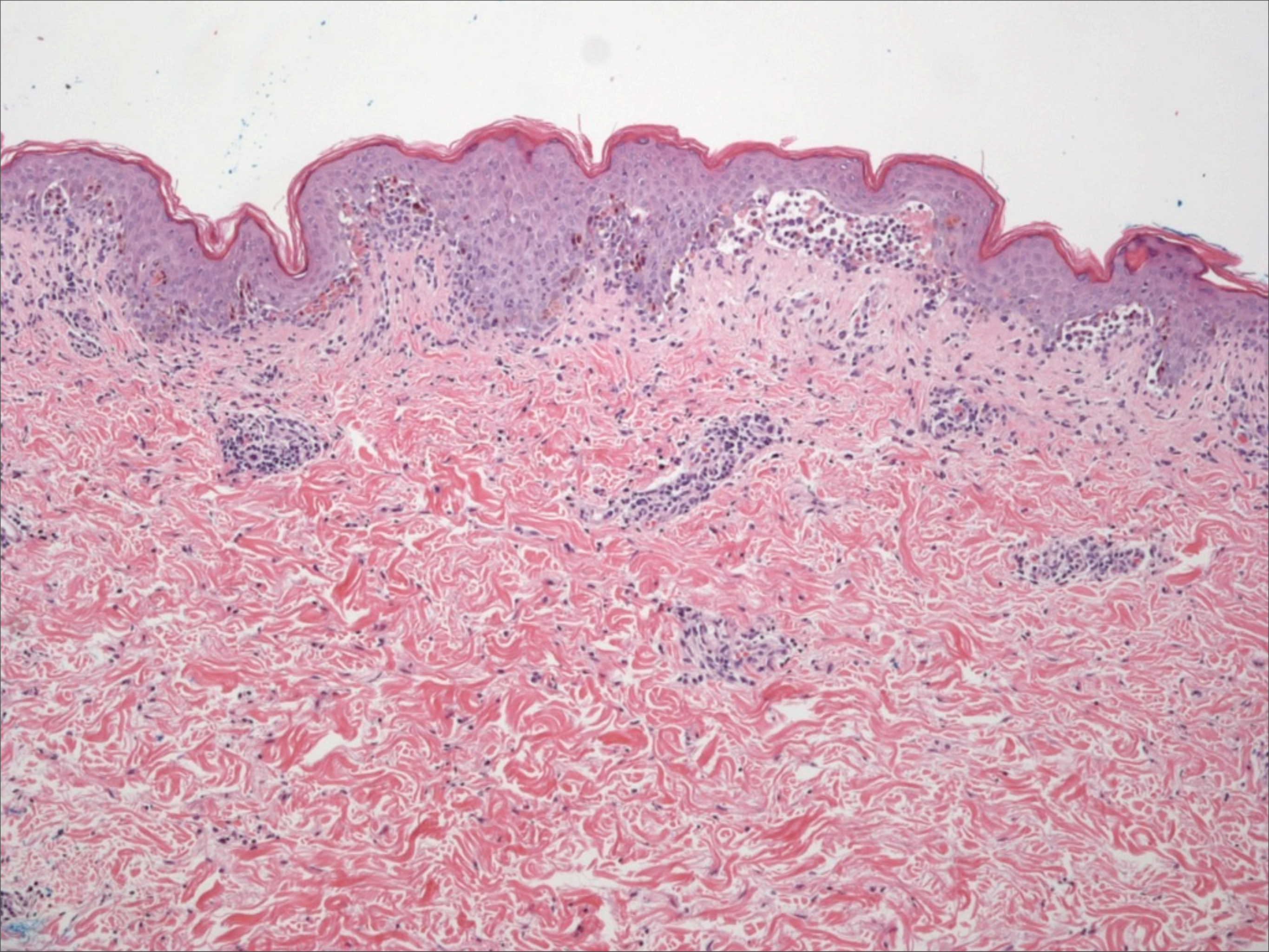
Spindle cells in
storiform configuration

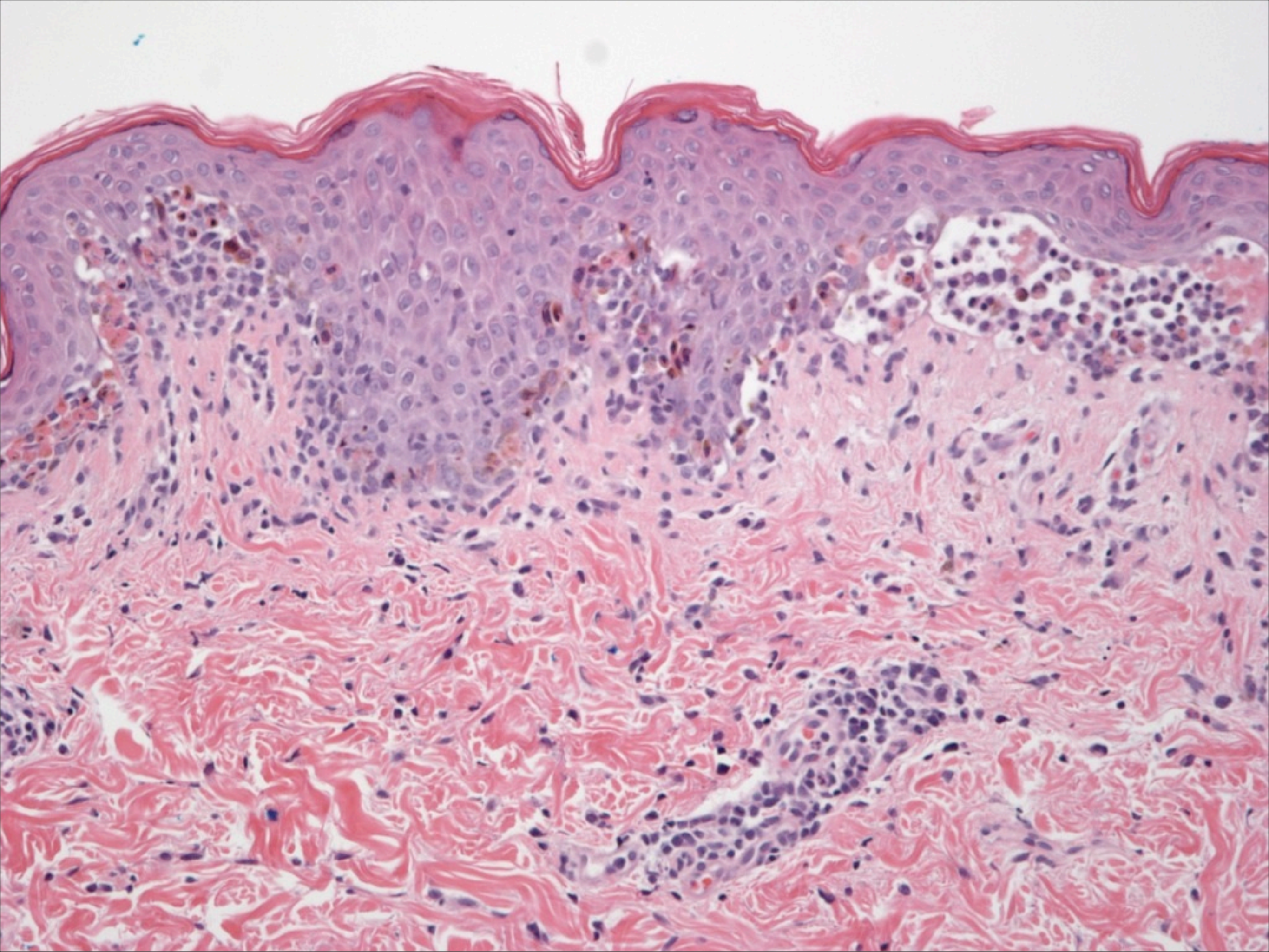
Adipocytes pulled into
papillary dermis with
“Swiss-cheese” pattern

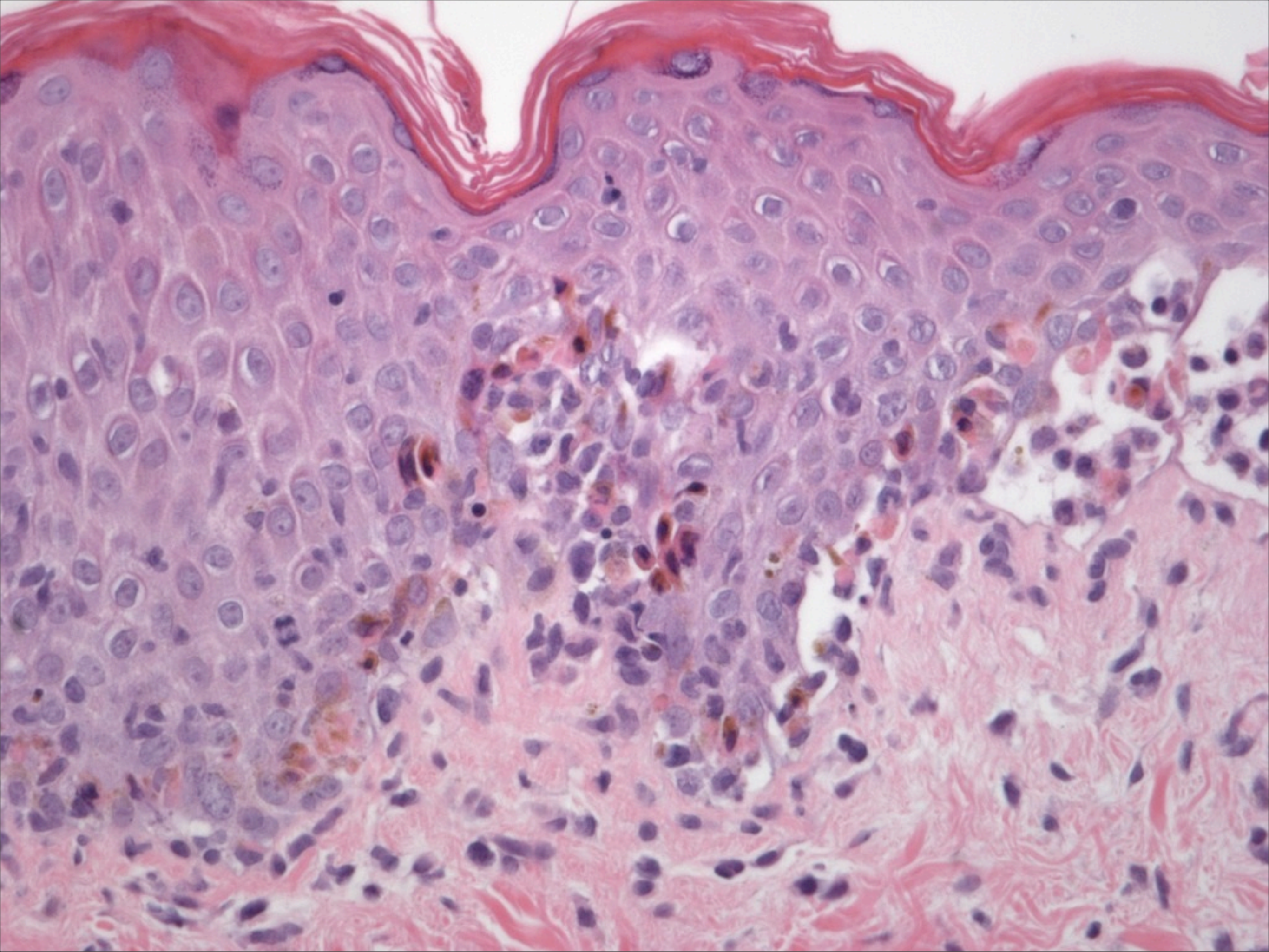
Minimal Cytologic Atypia

Confirm with CD34 positivity

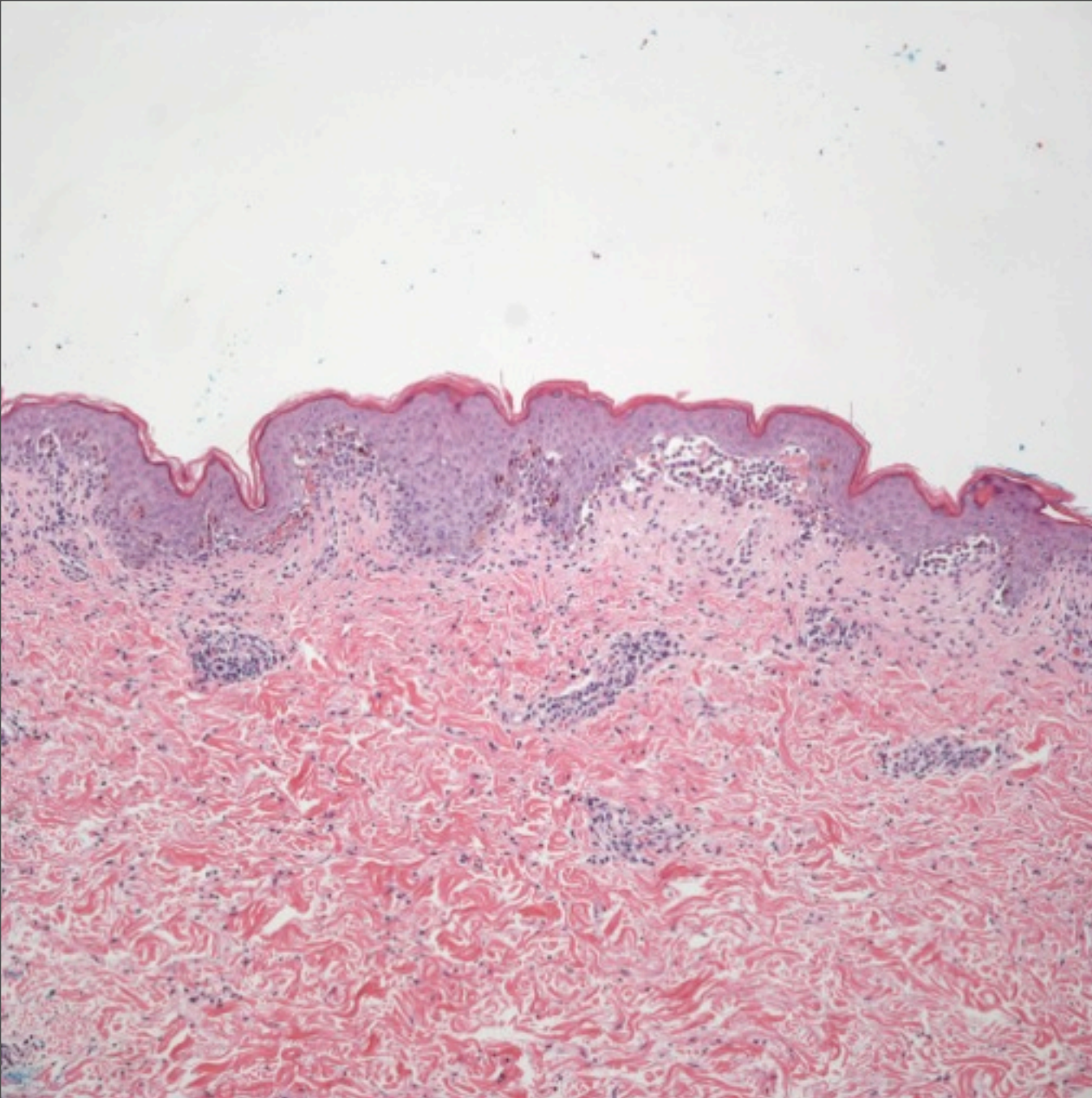








Erythema Multiforme

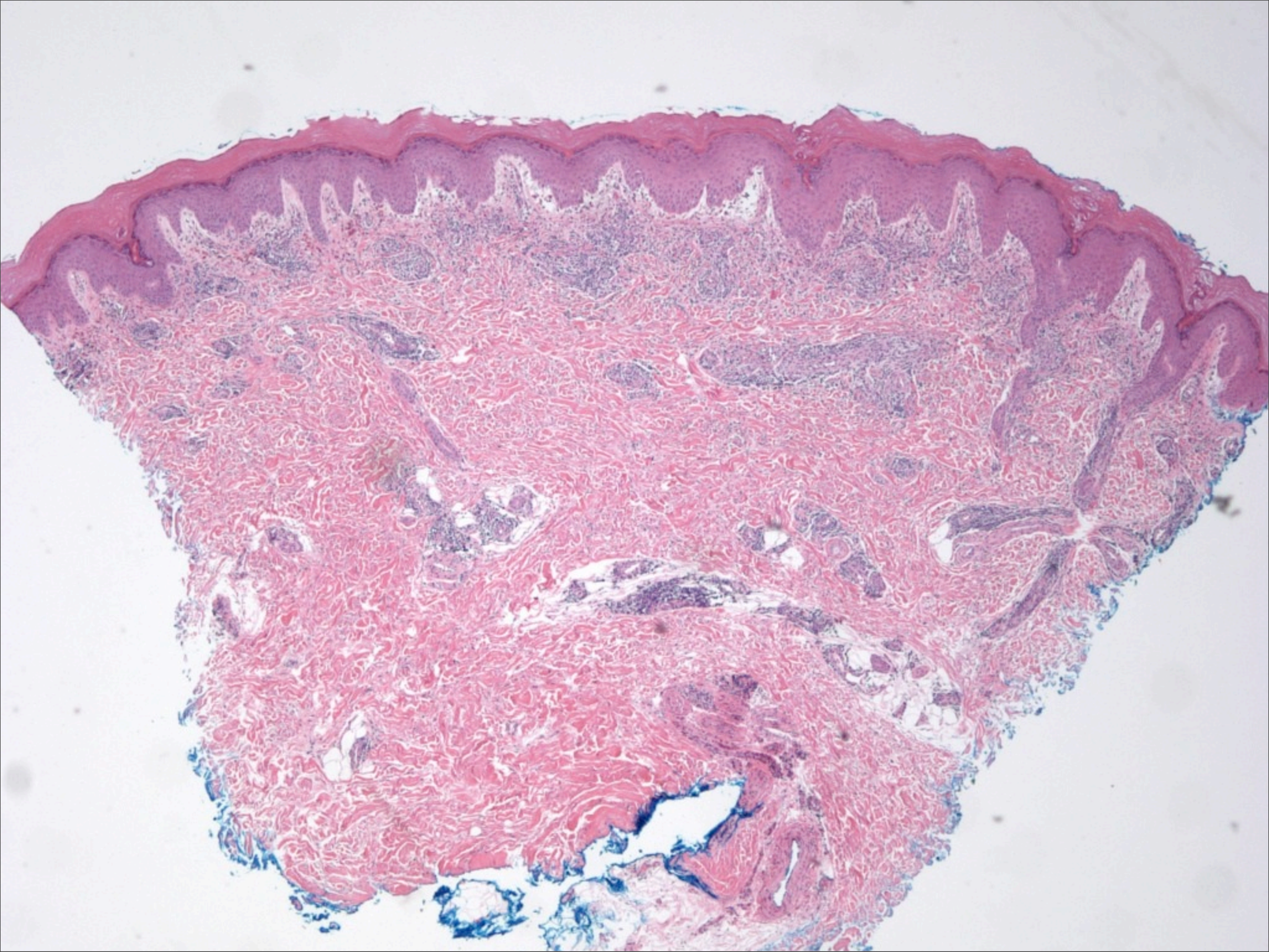


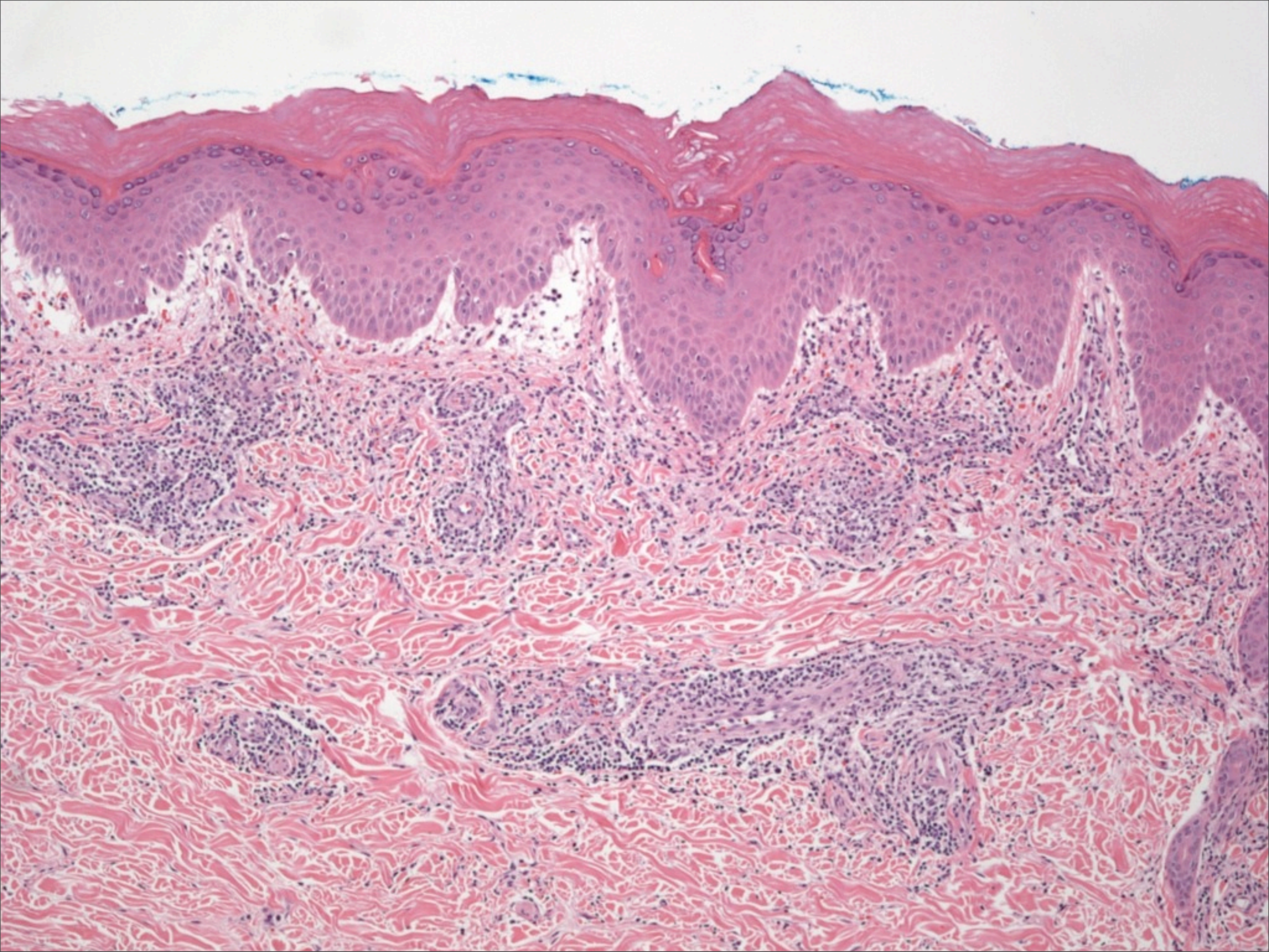
Acute Interface Dermatitis
with Lymphocytes

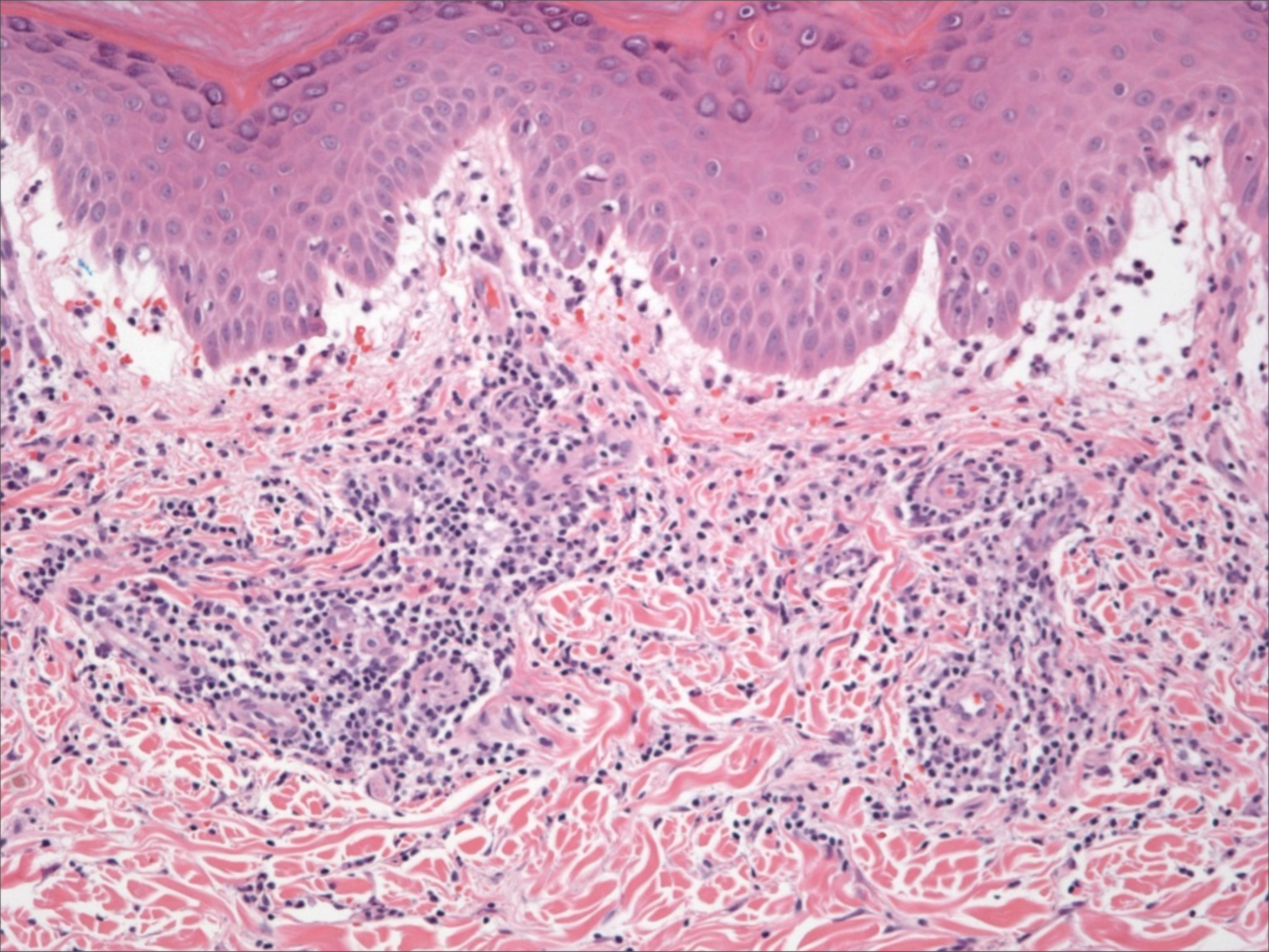
Variable eosinophils

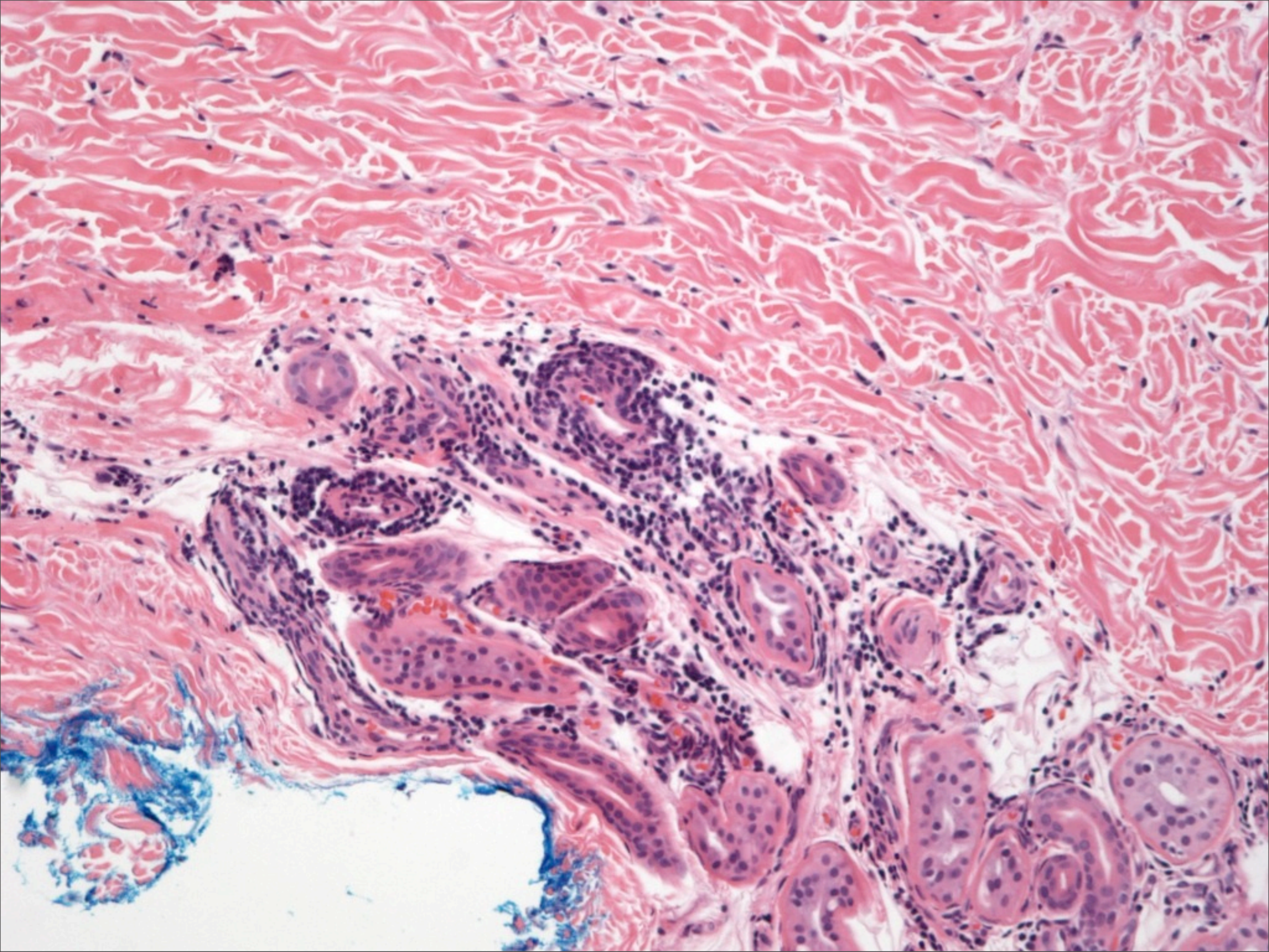
Dyskeratotic keratinocytes

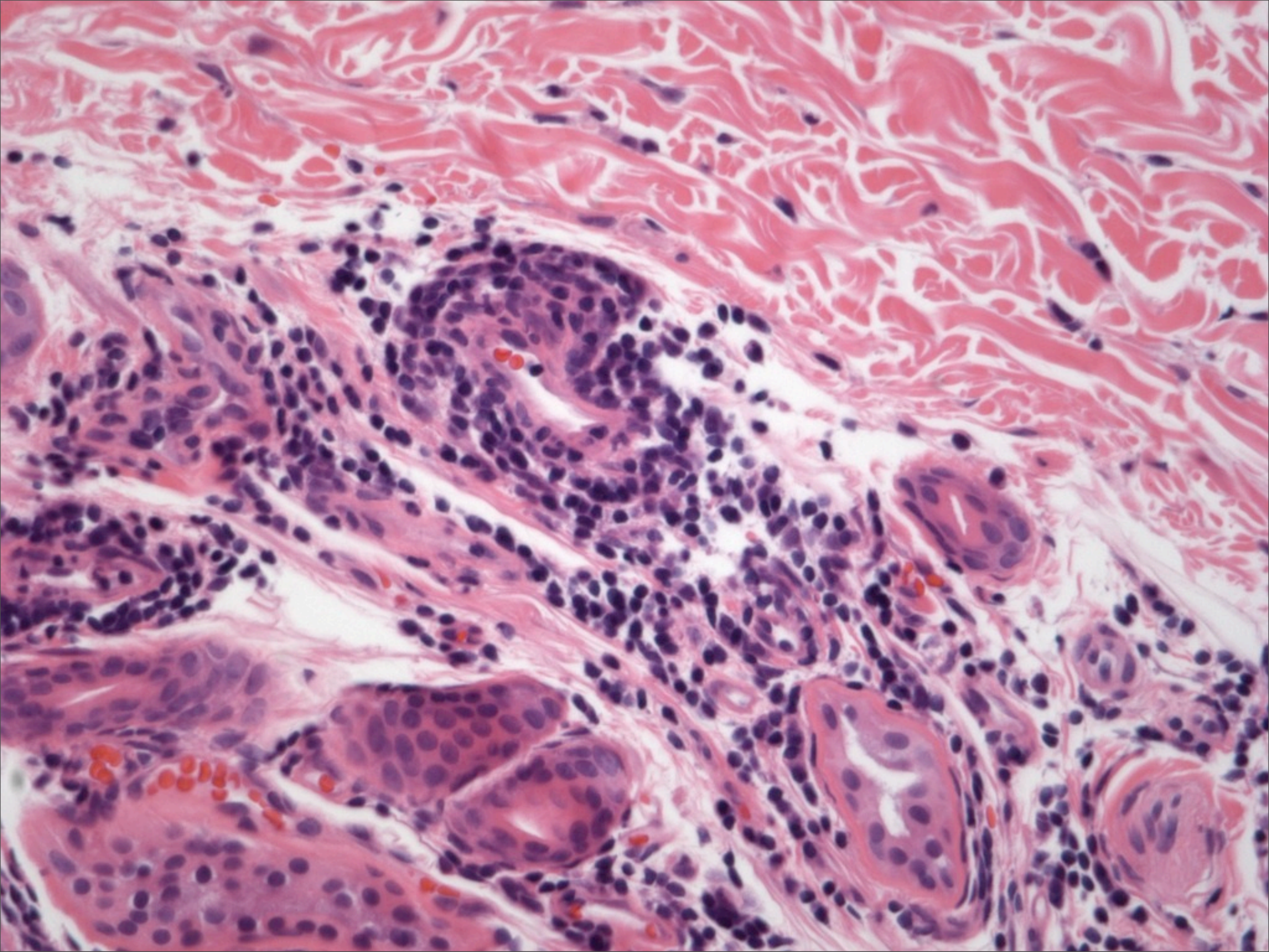
May show subepidermal vesicle/blister



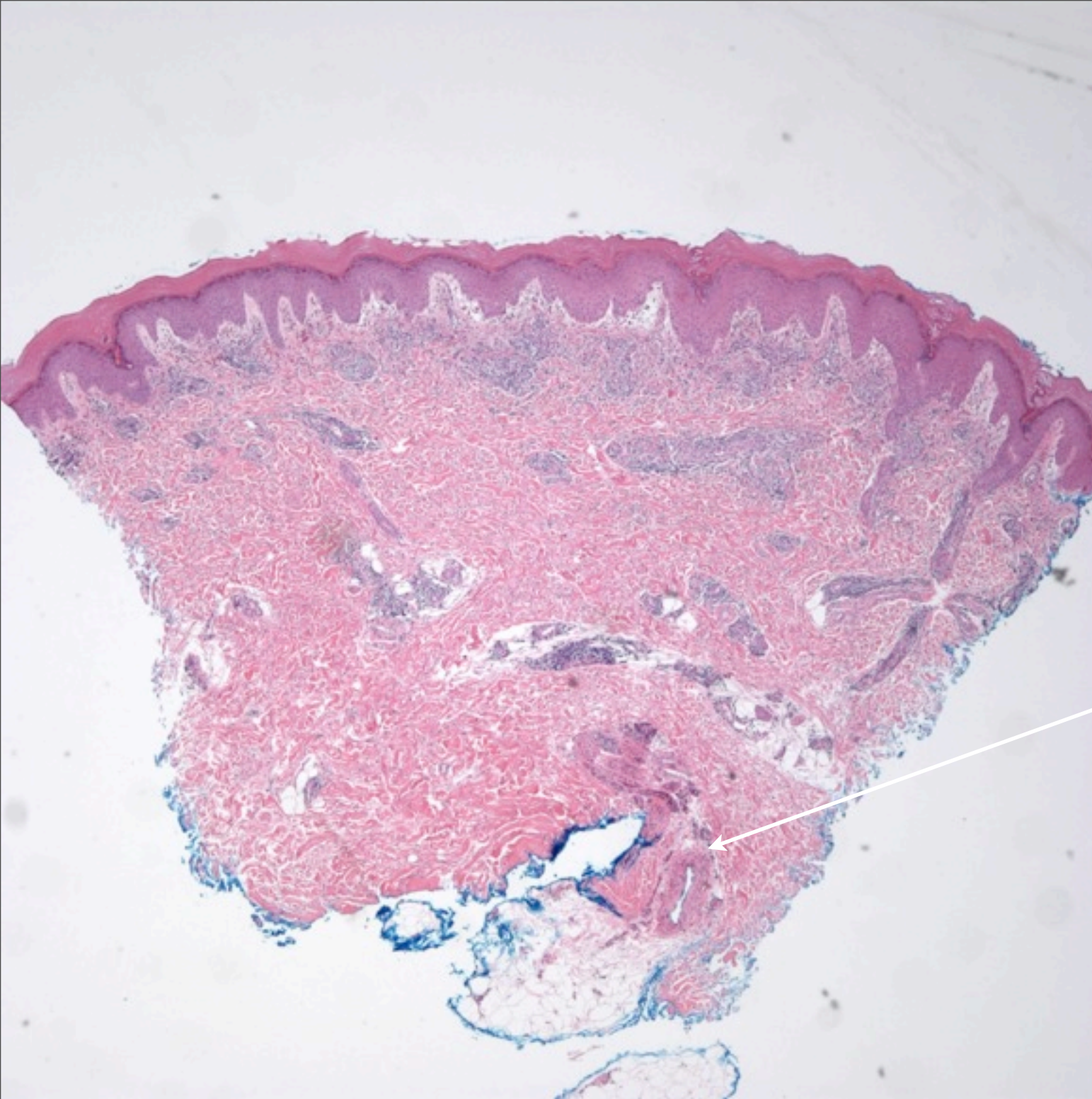








Chillblains (Perniosis)



Variable dermal
mucinosis

May show
lymphocytic vasculitis

Lichenoid interface dermatitis
Superficial and Deep Perivascular
and Periadnexal Lymphocytic Infiltrate